Physical examination of a 23-year-old man diagnosed with chronic hepatitis shows corneal changes that are visible to the naked eye, as shown in the image below.

This patient is most likely to have which of the following conditions?

A. Pulmonary emphysema

This patient is most likely to have which of the following conditions?

- A. Pulmonary emphysema
- B. Diabetes mellitus
- C. Basal ganglia atrophy
- D. Renal cancer
- E. Hypertrophic cardiomyopathy
- F. Congenital deafness

Submit

This patient is most likely to have which of the following conditions?

- A. Pulmonary emphysema (2%)
- B. Diabetes mellitus (14%)
- ✓ C. Basal ganglia atrophy (68%)
- D. Renal cancer (3%)
- E. Hypertrophic cardiomyopathy (7%)
- F. Congenital deafness (3%)

Omitted
Correct answer

68%
Answered correctly

10 secs
Time Spent

04/10/2020
Last Updated

The image demonstrates a Kayser-Fleischer ring, an ophthalmologic finding most strongly associated with Wilson's disease (although it can also be seen in chronic cholestatic diseases such as primary biliary cirrhosis). Kayser-Fleischer rings are best identified on slit-lamp examination, but they can be observed grossly, especially with long-standing, untreated disease. The rings are formed through the granular deposition of copper within Descemet's membrane in the cornea.

Wilson's disease is a rare, autosomal recessive disease most often identified in individuals 5-40 years old. The genetic mutations associated with Wilson's disease hinder copper metabolism by reducing the formation and secretion of ceruloplasmin and decreasing hepatic secretion of copper into the biliary system. Copper is a pro-oxidant and causes damage to hepatic tissue through the generation of free radicals. Eventually, it leaks from injured hepatocytes into the circulation to be deposited in various tissues, including the cornea and basal ganglia. Atrophy of the basal ganglia then ensues.

Treatment is life-long and focuses on removing accumulated copper in the tissues and preventing its re-accumulation. First-line medications include copper chelators such as d-penicillamine and trientine.

(Choice A) Pulmonary emphysema commonly develops in patients with alpha-1 antitrypsin deficiency.

(Choice B) Diabetes mellitus commonly develops in patients with advanced hemochromatosis. It has no association with Wilson's disease.

(Choice D) Renal cancer (clear cell carcinoma) occurs more frequently in patients with von Hippel-Lindau disease, not Wilson's disease.

(Choice E) Hypertrophic cardiomyopathy presenting in childhood and adolescence is an autosomal dominant disease involving the cardiac sarcomere. It is not associated with Wilson's disease.

(Choice F) Congenital deafness can develop secondary to numerous hereditary and nonhereditary conditions. Wilson's disease has no association with congenital deafness.

Educational objective:
The Kayser-Fleischer ring is an ophthalmologic finding most strongly associated with Wilson's disease. It is seen most frequently in patients with neuropsychiatric complications. Basal ganglia atrophy is typically present in these patients.

Wilson's disease is a rare, autosomal recessive disease most often identified in individuals 5-40 years old. The genetic mutations associated with Wilson's disease hinder copper metabolism by reducing the formation and secretion of ceruloplasmin and decreasing hepatic secretion of copper into the biliary system. Copper is a pro-oxidant and causes damage to hepatic tissue through the generation of free radicals. Eventually, it leaks from injured hepatocytes into the circulation to be deposited in various tissues, including the cornea and basal ganglia. Atrophy of the basal ganglia then ensues.

Treatment is life-long and focuses on removing accumulated copper in the tissues and preventing its re-accumulation. First-line medications include copper chelators such as d-penicillamine and trientine.

(Choice A) Pulmonary emphysema commonly develops in patients with alpha-1 antitrypsin deficiency.

(Choice B) Diabetes mellitus commonly develops in patients with advanced hemochromatosis. It has no association with Wilson's disease.

(Choice D) Renal cancer (clear cell carcinoma) occurs more frequently in patients with von Hippel-Lindau disease, not Wilson's disease.

(Choice E) Hypertrophic cardiomyopathy presenting in childhood and adolescence is an autosomal dominant disease involving the cardiac sarcomere. It is not associated with Wilson's disease.

(Choice F) Congenital deafness can develop secondary to numerous hereditary and nonhereditary conditions. Wilson's disease has no association with congenital deafness.

Educational objective:
The Kayser-Fleischer ring is an ophthalmologic finding most strongly associated with Wilson's disease. It is seen most frequently in patients with neuropsychiatric complications. Basal ganglia atrophy is typically present in these patients.

Pathology	Ophthalmology	Wilson disease
Subject	System	Topic

Copyright © UWorld. All rights reserved.

ENG
9:14 PM
7/10/2020

A 65-year-old male complains of bilateral visual difficulty that has progressed over the last year. Funduscopy reveals small yellow retinal lesions clustered in the macula. Which of the following would you expect most on visual field examination?

- A. Homonymous hemianopsia
- B. Binasal hemianopsia
- C. Bitemporal hemianopsia
- D. Arcuate scotomas
- E. Central scotomas

Submit

A 65-year-old male complains of bilateral visual difficulty that has progressed over the last year. Funduscopy reveals small yellow retinal lesions clustered in the macula. Which of the following would you expect most on visual field examination?

- A. Homonymous hemianopsia (2%)
- B. Binasal hemianopsia (1%)
- C. Bitemporal hemianopsia (5%)
- D. Arcuate scotomas (7%)
- ✓ E. Central scotomas (81%)

Omitted
Correct answer
E

81%
Answered correctly

01 sec
Time Spent

02/03/2020
Last Updated

Explanation

The macula is a yellowish spot approximately 1.5 mm in diameter located near the center of the retina. It is characterized histologically by the presence of densely packed cones, few overlying cells and no blood vessels. Each macular cone synapses to a single bipolar cell, which, in turn, synapses to a single ganglion cell. Due to this arrangement the visual acuity in the macula, and particularly the fovea, is greater than in any other area of the retina. The neural fibers that serve the macula transmit to an area of the occipital visual cortex that is separate from the area of representation of the peripheral fields (this area is also relatively large in size). Due to this peculiar cortical representation, macular sparing is common in lesions of the occipital cortex.

The macula is a yellowish spot approximately 1.5 mm in diameter located near the center of the retina. It is characterized histologically by the presence of densely packed cones, few overlying cells and no blood vessels. Each macular cone synapses to a single bipolar cell, which, in turn, synapses to a single ganglion cell. Due to this arrangement the visual acuity in the macula, and particularly the fovea, is greater than in any other area of the retina. The neural fibers that serve the macula transmit to an area of the occipital visual cortex that is separate from the area of representation of the peripheral fields (this area is also relatively large in size). Due to this peculiar cortical representation, macular sparing is common in lesions of the occipital cortex.

Macular lesions impair central vision and result in central scotomata **(Choice E)**. The term **scotoma** refers to any visual defect surrounded by a relatively unimpaired field of vision. Scotomas occur due to pathologic processes that involve parts of the retina or optic nerve. Examples of such processes include demyelinating diseases such as multiple sclerosis, diabetic retinopathy and retinitis pigmentosa. Pathologic processes that involve the entire optic nerve lead to monocular blindness.

The patient described in this clinical vignette is likely to have macular degeneration (MD). This disorder is frequently age-related, and is the most common cause of blindness in people over 50 years old in the US. Macular degeneration is characterized by progressive loss of central vision due to deposition of fatty tissue (drusen) behind the retina (dry MD) and neovascularization of the retina (wet MD).

(Choice A) Homonymous hemianopsia is a loss of vision in the same side of the visual field in both eyes. It occurs due to transection of the contralateral optic tract, the fibers of the visual pathway linking the optic chiasm to the lateral geniculate body.

(Choice B) Binasal hemianopsia is a loss of vision in the nasal fields of both eyes. It is caused by pressure to the lateral areas of the optic chiasm. This may result from calcified carotid arteries.

(Choice C) Bitemporal hemianopsia is a loss of vision in the temporal fields of both eyes. It is caused by compression of the medial part of the optic chiasm, where the nasal fibers decussate, most commonly by a pituitary adenoma.

(Choice D) Arcuate scotomas occur due to damage to a particular region of the optic nerve head. The resulting visual field defect follows the arcuate shape of the nerve fiber pattern.

Educational Objective:

Macular lesions impair central vision and result in central scotomata **(Choice E)**. The term **scotoma** refers to any visual defect surrounded by a relatively unimpaired field of vision. Scotomas occur due to pathologic processes that involve parts of the retina or optic nerve. Examples of such processes include demyelinating diseases such as multiple sclerosis, diabetic retinopathy and retinitis pigmentosa. Pathologic processes that involve the entire optic nerve lead to monocular blindness.

The patient described in this clinical vignette is likely to have macular degeneration (MD). This disorder is frequently age-related, and is the most common cause of blindness in people over 50 years old in the US. Macular degeneration is characterized by progressive loss of central vision due to deposition of fatty tissue (drusen) behind the retina (dry MD) and neovascularization of the retina (wet MD).

(Choice A) Homonymous hemianopsia is a loss of vision in the same side of the visual field in both eyes. It occurs due to transection of the contralateral optic tract, the fibers of the visual pathway linking the optic chiasm to the lateral geniculate body.

(Choice B) Binasal hemianopsia is a loss of vision in the nasal fields of both eyes. It is caused by pressure to the lateral areas of the optic chiasm. This may result from calcified carotid arteries.

(Choice C) Bitemporal hemianopsia is a loss of vision in the temporal fields of both eyes. It is caused by compression of the medial part of the optic chiasm, where the nasal fibers decussate, most commonly by a pituitary adenoma.

(Choice D) Arcuate scotomas occur due to damage to a particular region of the optic nerve head. The resulting visual field defect follows the arcuate shape of the nerve fiber pattern.

Educational Objective:
A scotoma is a visual field defect that occurs due to a pathologic process that involves parts of the retina or the optic nerve resulting in a discrete area of altered vision surrounded by zones of normal vision. Lesions of the macula cause central scotomas.

Pathophysiology	Ophthalmology	Macular degeneration
Subject	System	Topic

Copyright © UWorld. All rights reserved.

Macular lesions impair central vision and result in central scotomata **(Choice E)**. The term **scotoma** refers to any visual defect surrounded by a relatively unimpaired field of vision. Scotomas occur due to pathologic processes that involve parts of the retina or optic nerve. Examples of such processes include demyelinating diseases such as multiple sclerosis, diabetic retinopathy and retinitis pigmentosa. Pathologic processes that involve the entire optic nerve lead to monocular blindness.

The patient described in this clinical vignette is likely to have macular degeneration (MD). This disorder is frequently age-related, and is the most common cause of blindness in people over 50 years old in the US. Macular degeneration is characterized by progressive loss of central vision due to deposition of fatty tissue (drusen) behind the retina (dry MD) and neovascularization of the retina (wet MD).

(Choice A) Homonymous hemianopsia is a loss of vision in the same side of the visual field in both eyes. It occurs due to transection of the contralateral optic tract, the fibers of the visual pathway linking the optic chiasm to the lateral geniculate body.

(Choice B) Binasal hemianopsia is a loss of vision in the nasal fields of both eyes. It is caused by pressure to the lateral areas of the optic chiasm. This may result from calcified carotid arteries.

(Choice C) Bitemporal hemianopsia is a loss of vision in the temporal fields of both eyes. It is caused by compression of the medial part of the optic chiasm, where the nasal fibers decussate, most commonly by a pituitary adenoma.

(Choice D) Arcuate scotomas occur due to damage to a particular region of the optic nerve head. The resulting visual field defect follows the arcuate shape of the nerve fiber pattern.

Educational Objective:
A scotoma is a visual field defect that occurs due to a pathologic process that involves parts of the retina or the optic nerve resulting in a discrete area of altered vision surrounded by zones of normal vision. Lesions of the macula cause central scotomas.

Pathophysiology	Ophthalmology	Macular degeneration
Subject	System	Topic

Copyright © UWorld. All rights reserved.

ENG
9:28 PM
7/10/2020

A 58-year-old man comes to the emergency department due to vision disturbances. Over the past several weeks, the patient has had intermittent episodes in which he sees everything tinted with blue. His vision returned to normal within a few hours each time. When he woke up today, vision in the left eye was blurry. He has had no eye pain, conjunctival redness, or headache. The patient has tingling and numbness in the feet due to diabetic neuropathy, which is unchanged, and reports no other focal weakness or sensory loss. Medical history is notable for hypertension, type 2 diabetes mellitus, hyperlipidemia, and erectile dysfunction. Vital signs are within normal limits. Physical examination shows an afferent pupillary defect, decreased visual acuity, and optic disc edema in the left eye. Discontinuing which of the following medications may improve this patient's vision?

- A. Amitriptyline
- B. Atorvastatin
- C. Canagliflozin
- D. Metformin
- E. Ramipril
- F. Sildenafil

Submit

A 58-year-old man comes to the emergency department due to vision disturbances. Over the past several weeks, the patient has had intermittent episodes in which he sees everything tinted with blue. His vision returned to normal within a few hours each time. When he woke up today, vision in the left eye was blurry. He has had no eye pain, conjunctival redness, or headache. The patient has tingling and numbness in the feet due to diabetic neuropathy, which is unchanged, and reports no other focal weakness or sensory loss. Medical history is notable for hypertension, type 2 diabetes mellitus, hyperlipidemia, and erectile dysfunction. Vital signs are within normal limits. Physical examination shows an afferent pupillary defect, decreased visual acuity, and optic disc edema in the left eye. Discontinuing which of the following medications may improve this patient's vision?

- A. Amitriptyline (23%)
- B. Atorvastatin (1%)
- C. Canagliflozin (7%)
- D. Metformin (2%)
- E. Ramipril (3%)
- ✓ F. Sildenafil (62%)

Omitted
Correct answer
F

62%
Answered correctly

04 secs
Time Spent

02/19/2020
Last Updated

Explanation

Explanation

Adverse effects of phosphodiesterase 5 inhibitors	
Cardiovascular	• **Hypotension** (especially with nitrates, alpha blockers)
Ocular	• Blue discoloration of vision • Nonarteritic anterior ischemic optic neuropathy
Genitourinary	• **Priapism**
Other	• Flushing • Headache • Hearing loss

Normal male erectile function involves interplay between psychological and physical stimulation and the vascular, neurologic, and hormonal systems. On a vascular level, penile erection is induced by increased blood flow to the corpora cavernosa and corpus spongiosum accompanied by decreased outflow. Endothelial factors required for erection include formation of nitric oxide, which induces formation of cyclic GMP (cGMP), which in turn mediates vascular smooth muscle relaxation. cGMP is inactivated by cGMP phosphodiesterase (PDE) (ie, PDE5), which cleaves cGMP and terminates penile erection.

PDE5 inhibitors (eg, sildenafil, tadalafil) are widely used, first-line agents for treatment of **erectile dysfunction** (ED). PDE5 inhibitors increase activity of cGMP in the penile corpora, leading to greater and more prolonged tumescence in men with ED.

However, PDE5 inhibitors can also inhibit PDE6 in the retina, which is involved in color vision. Patients experience this effect as a transient **bluish discoloration** to vision. Less common ocular effects of PDE5 inhibitors include **nonarteritic anterior ischemic optic neuropathy**, which presents with sudden monocular vision loss associated with an afferent pupillary defect, decreased visual acuity, and optic disc edema.

(Choice A) The anticholinergic effects of tricyclic antidepressants (eg, amitriptyline) can cause dry eye, blurred vision, and triggering of angle-closure glaucoma (ie, ocular pain, headache, unilateral vision loss). Discoloration of vision is not typical.

which in turn mediates vascular smooth muscle relaxation. cGMP is inactivated by cGMP phosphodiesterase (PDE) (ie, PDE5), which cleaves cGMP and terminates penile erection.

PDE5 inhibitors (eg, sildenafil, tadalafil) are widely used, first-line agents for treatment of **erectile dysfunction** (ED). PDE5 inhibitors increase activity of cGMP in the penile corpora, leading to greater and more prolonged tumescence in men with ED.

However, PDE5 inhibitors can also inhibit PDE6 in the retina, which is involved in color vision. Patients experience this effect as a transient **bluish discoloration** to vision. Less common ocular effects of PDE5 inhibitors include **nonarteritic anterior ischemic optic neuropathy**, which presents with sudden monocular vision loss associated with an afferent pupillary defect, decreased visual acuity, and optic disc edema.

(Choice A) The anticholinergic effects of tricyclic antidepressants (eg, amitriptyline) can cause dry eye, blurred vision, and triggering of angle-closure glaucoma (ie, ocular pain, headache, unilateral vision loss). Discoloration of vision is not typical.

(Choice B) Important side effects of statins (eg, atorvastatin) include myopathy and hepatic toxicity. Statins may have a small effect on the risk of cataract but otherwise have few ocular manifestations.

(Choice C) Sodium-glucose cotransporter 2 inhibitors (eg, canagliflozin) induce increased renal excretion of glucose and water. Most of the side effects (eg, hypotension, urinary tract infection) are related to glucosuria and fluid shifts; visual symptoms are not common.

(Choice D) Metformin most commonly causes gastrointestinal side effects (eg, nausea, diarrhea). Lactic acidosis is a potentially serious but rare complication. Visual side effects are not a significant concern.

(Choice E) Side effects of ACE inhibitors (eg, ramipril) are primarily related to renal function (eg, hyperkalemia, acute kidney injury) or blood pressure (eg, dizziness, hypotension). Patients may also develop a dry cough due to an increase in circulating bradykinin.

Educational objective:
Phosphodiesterase 5 inhibitors (eg, sildenafil, tadalafil) can cause a transient bluish discoloration to vision. Less common ocular effects include sudden monocular vision loss due to nonarteritic anterior ischemic optic neuropathy; findings include an afferent pupillary defect, decreased visual acuity, and optic disc edema.

References

discoloration to vision. Less common ocular effects of PDE5 inhibitors include **nonarteritic anterior ischemic optic neuropathy**, which presents with sudden monocular vision loss associated with an afferent pupillary defect, decreased visual acuity, and optic disc edema.

(Choice A) The anticholinergic effects of tricyclic antidepressants (eg, amitriptyline) can cause dry eye, blurred vision, and triggering of angle-closure glaucoma (ie, ocular pain, headache, unilateral vision loss). Discoloration of vision is not typical.

(Choice B) Important side effects of statins (eg, atorvastatin) include myopathy and hepatic toxicity. Statins may have a small effect on the risk of cataract but otherwise have few ocular manifestations.

(Choice C) Sodium-glucose cotransporter 2 inhibitors (eg, canagliflozin) induce increased renal excretion of glucose and water. Most of the side effects (eg, hypotension, urinary tract infection) are related to glucosuria and fluid shifts; visual symptoms are not common.

(Choice D) Metformin most commonly causes gastrointestinal side effects (eg, nausea, diarrhea). Lactic acidosis is a potentially serious but rare complication. Visual side effects are not a significant concern.

(Choice E) Side effects of ACE inhibitors (eg, ramipril) are primarily related to renal function (eg, hyperkalemia, acute kidney injury) or blood pressure (eg, dizziness, hypotension). Patients may also develop a dry cough due to an increase in circulating bradykinin.

Educational objective:
Phosphodiesterase 5 inhibitors (eg, sildenafil, tadalafil) can cause a transient bluish discoloration to vision. Less common ocular effects include sudden monocular vision loss due to nonarteritic anterior ischemic optic neuropathy; findings include an afferent pupillary defect, decreased visual acuity, and optic disc edema.

References

- Acute nonarteritic anterior ischemic optic neuropathy and exposure to phosphodiesterase type 5 inhibitors.

Pharmacology	Ophthalmology	Phosphodiesterase inhibitors
Subject	System	Topic

Copyright © UWorld. All rights reserved.

1
2
3
4
5
6
7
8
9
10
11
12
13
14
15
16
17
18
19
20
21

A 17-year-old boy is brought to the clinic due to poor vision at night. The patient developed mild difficulty seeing at night about 4 months ago, and it has slowly worsened. Visual field examination shows visual loss in the midperiphery. External eye examination reveals normal tear formation. Funduscopic examination shows bilateral optic disc pallor, attenuation of retinal vessels, and areas of dark discoloration in the retina. Which of the following is the most likely mechanism of this patient's visual impairment?

A. Biallelic inactivation of *RB1* gene

B. Genetic progressive retinal dystrophy

C. Increased intracranial pressure

D. Poor aqueous outflow due to narrow angle

E. Retinal artery occlusion

Submit

ENG
9:28 PM
7/10/2020

A 17-year-old boy is brought to the clinic due to poor vision at night. The patient developed mild difficulty seeing at night about 4 months ago, and it has slowly worsened. Visual field examination shows visual loss in the midperiphery. External eye examination reveals normal tear formation. Funduscopic examination shows bilateral optic disc pallor, attenuation of retinal vessels, and areas of dark discoloration in the retina. Which of the following is the most likely mechanism of this patient's visual impairment?

- A. Biallelic inactivation of *RB1* gene (16%)
- ✓ B. Genetic progressive retinal dystrophy (59%)
- C. Increased intracranial pressure (8%)
- D. Poor aqueous outflow due to narrow angle (4%)
- E. Retinal artery occlusion (10%)

Omitted
Correct answer
B

59%
Answered correctly

02 secs
Time Spent

05/15/2020
Last Updated

Explanation

Retinitis pigmentosa	
Etiology	• Genetic dystrophy • Progressive retinal degeneration (photoreceptors, pigmented epithelium)

Retinitis pigmentosa	
Etiology	• Genetic dystrophy • Progressive retinal degeneration (photoreceptors, pigmented epithelium)

Clinical features	• Loss of rods:
	  ◦ Night blindness
	  ◦ Peripheral visual field loss
	• Loss of cones:
	  ◦ Decreased central visual acuity (late finding)

Funduscopic changes	• Retinal vessel attenuation (likely due to altered metabolic demand) • Optic disc pallor (optic nerve atrophy and gliosis) • Pigment accumulation (characteristic bone-spicule pattern around vessels)

This patient has poor night vision, visual field loss, and funduscopic changes (eg, pigment accumulation, optic disc pallor, retinal vessel attenuation) consistent with **retinitis pigmentosa**, a genetic disease characterized by **progressive dystrophy** of the retinal pigmented epithelium and **photoreceptors** (eg, rods, cones).

Rods, which are highly metabolically active and most prevalent in the periphery, are affected first, leading to the initial manifestations of **progressive night blindness** and **loss of peripheral vision**. Early funduscopic changes include retinal vessel attenuation (ie, narrow vessels likely due to alterations in retinal metabolic demand) and a waxy, pale optic disc (due to optic nerve atrophy and gliosis).

In advanced disease, loss of cones (most prevalent in the central retina) causes decreased central visual acuity. Degeneration of retinal pigmented epithelial cells releases **pigment**, which **deposits** in a characteristic **bone-spicule pattern** over the course of the disease.

(Choice A) Retinoblastoma, which is caused by inactivation of both alleles of the *RB1* gene (ie, 2-hit hypothesis), typically presents in the first 3 years of life with leukocoria (ie, white pupillary reflex), strabismus, and a creamy-white mass on funduscopic examination.

This patient has poor night vision, visual field loss, and funduscopic changes (eg, pigment accumulation, optic disc pallor, retinal vessel attenuation) consistent with **retinitis pigmentosa**, a genetic disease characterized by **progressive dystrophy** of the retinal pigmented epithelium and **photoreceptors** (eg, rods, cones).

Rods, which are highly metabolically active and most prevalent in the periphery, are affected first, leading to the initial manifestations of **progressive night blindness** and **loss of peripheral vision**. Early funduscopic changes include retinal vessel attenuation (ie, narrow vessels likely due to alterations in retinal metabolic demand) and a waxy, pale optic disc (due to optic nerve atrophy and gliosis).

In advanced disease, loss of cones (most prevalent in the central retina) causes decreased central visual acuity. Degeneration of retinal pigmented epithelial cells releases **pigment**, which **deposits** in a characteristic **bone-spicule pattern** over the course of the disease.

(Choice A) Retinoblastoma, which is caused by inactivation of both alleles of the *RB1* gene (ie, 2-hit hypothesis), typically presents in the first 3 years of life with leukocoria (ie, white pupillary reflex), strabismus, and a creamy-white mass on funduscopic examination.

(Choice C) Increased intracranial pressure can be associated with transient visual obscuration and decreased visual acuity. However, other symptoms (eg, headache, vomiting) are also typically present and papilledema with blurred optic disc margins would be seen on funduscopy.

(Choice D) Angle-closure glaucoma occurs due to narrowing of the angle between the iris and the cornea, which blocks aqueous outflow. Patients typically have acute eye pain and vision loss with conjunctival erythema, cornea edema, and a mid-dilated, poorly reactive pupil. Optic nerve atrophy secondary to chronically increased intraocular pressure results in optic nerve cupping on funduscopy.

(Choice E) Central retinal artery occlusion typically presents with unilateral painless acute vision loss in patients age >40 with thromboembolic risk factors (eg, hypertension). Retinal whitening and a cherry-red macula are the characteristic funduscopic changes.

Educational objective:
Retinitis pigmentosa is a genetic condition resulting in progressive dystrophy of retinal pigmented epithelium and photoreceptors. Patients typically present with progressive night blindness and loss of peripheral vision due to early loss of rods, which are highly metabolically active. Funduscopic examination may show dark pigments deposited in a bone-spicule pattern in addition to retinal vessel attenuation and optic disc pallor.

1
2
3
4
5
6
7
8
9
10
11
12
13
14
15
16
17
18
19
20
21

Exhibit Display

Retinitis pigmentosa

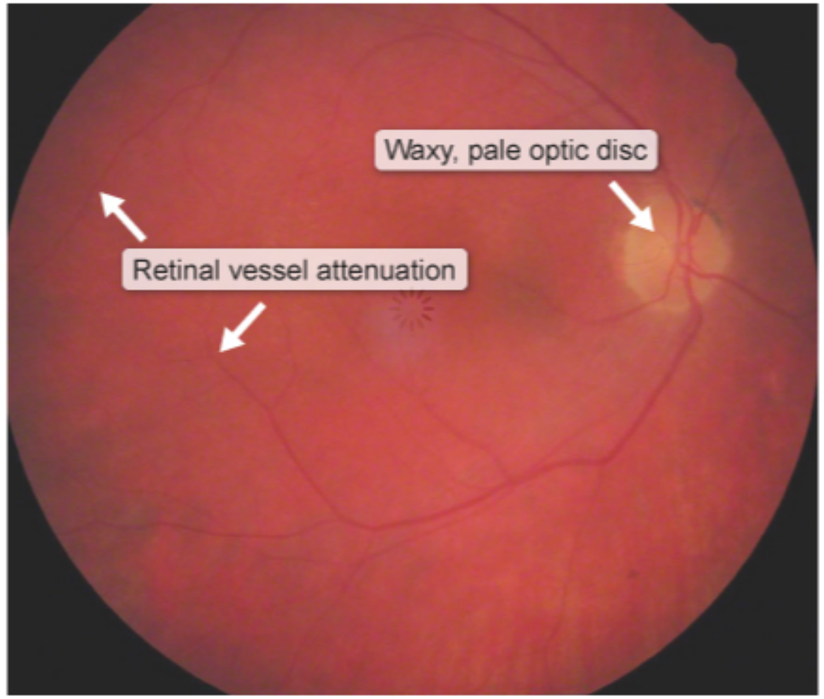

©UWorld

Zoom In
Zoom Out
Reset
Add To Flash Card

ENG
9:28 PM
7/10/2020

1
2
3
4
5
6
7
8
9
10
11
12
13
14
15
16
17
18
19
20
21

Exhibit Display

Normal eyes & white reflex

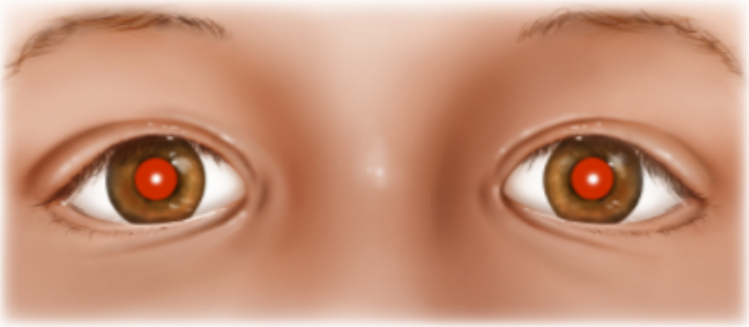

Normal eyes
Red reflexes & corneal light reflexes are equal.

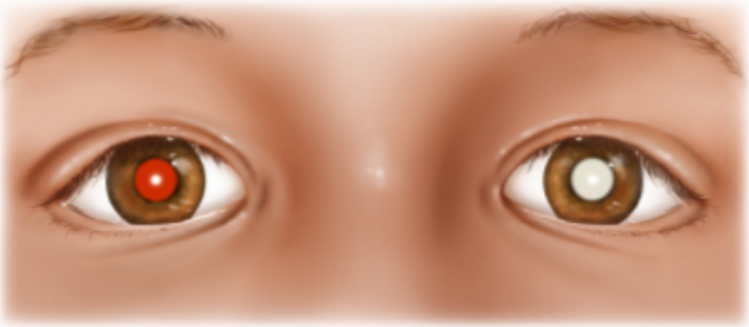

Absent reflex
White reflex on abnormal eye can result from opacities of the lens (eg, cataract) or tumor (eg, retinoblastoma).

©UWorld

Zoom In
Zoom Out
Reset
Add To Flash Card

ENG
9:28 PM
7/10/2020

1
2
3
4
5
6
7
8
9
10
11
12
13
14
15
16
17
18
19
20
21

Exhibit Display

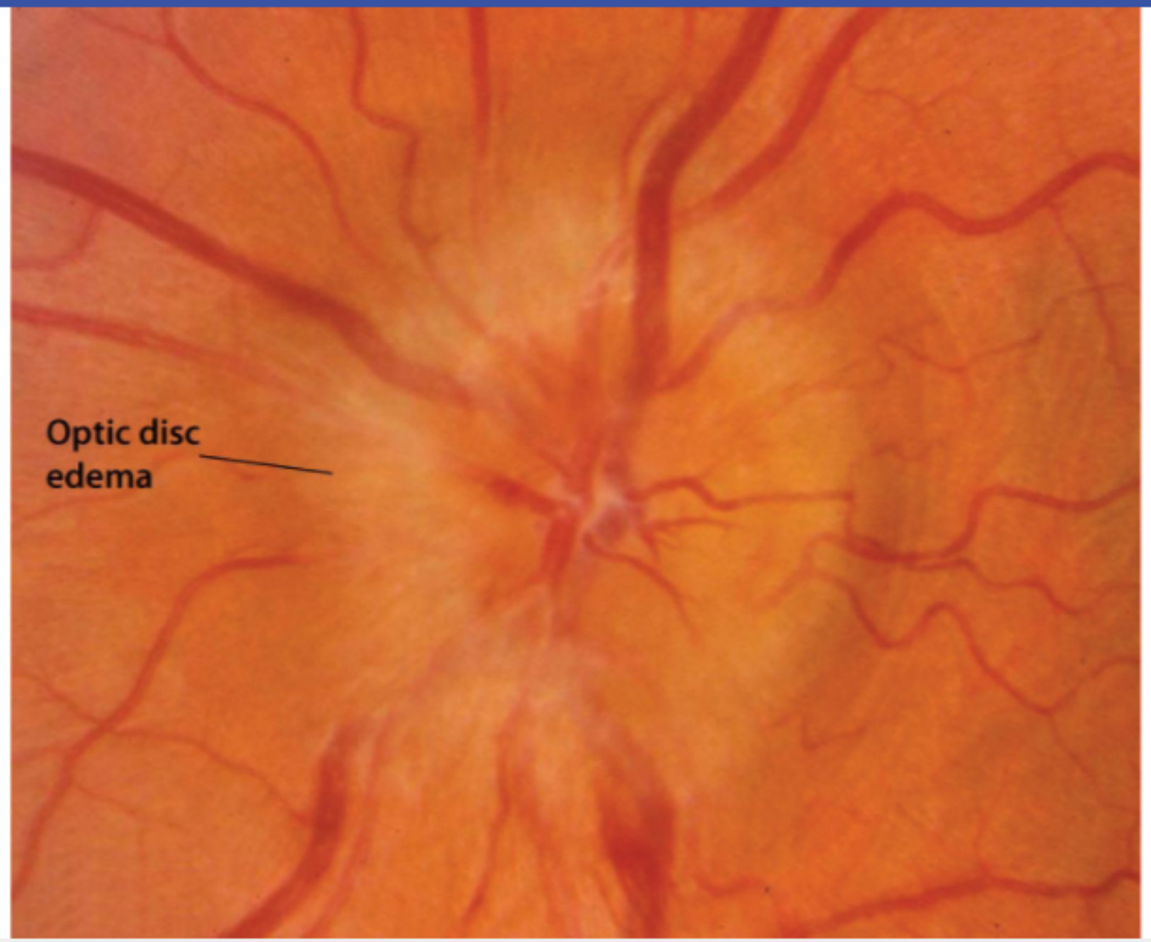

Zoom In
Zoom Out
Reset
Add To Flash Card

ENG
9:29 PM
7/10/2020

1
2
3
4
5
6
7
8
9
10
11
12
13
14
15
16
17
18
19
20
21

Exhibit Display

Angle-closure glaucoma

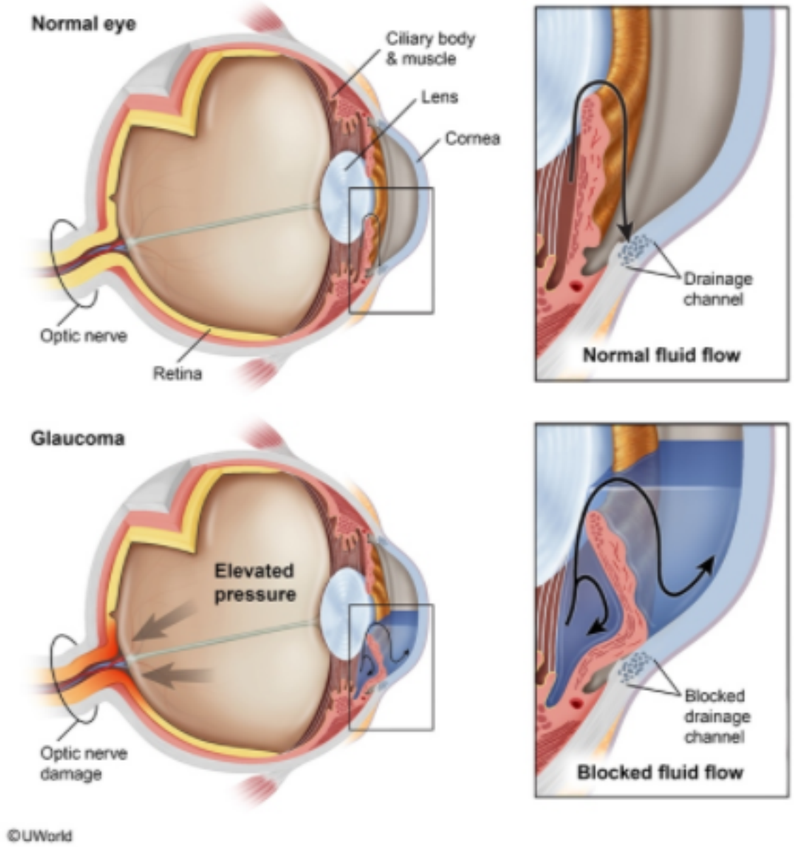

Zoom In
Zoom Out
Reset
Add To Flash Card

ENG
9:29 PM
7/10/2020

1
2
3
4
5
6
7
8
9
10
11
12
13
14
15
16
17
18
19
20
21

Exhibit Display

Optic disc in glaucoma

Normal	Open-angle glaucoma
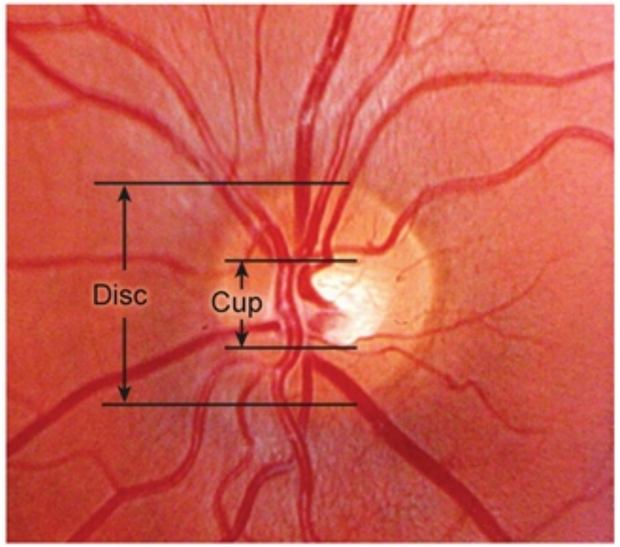	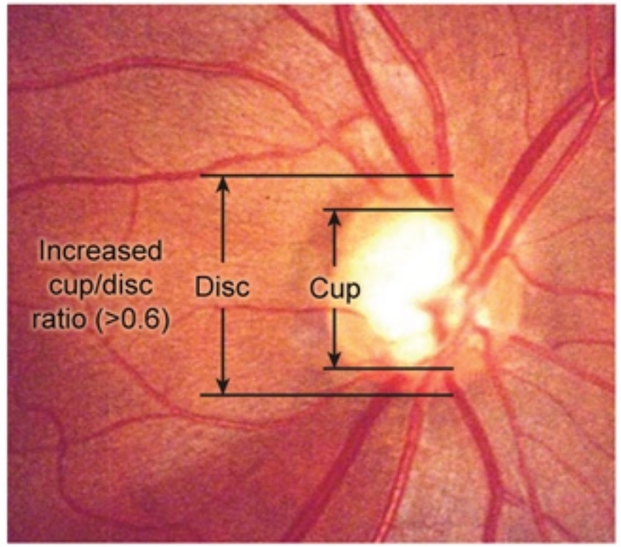
• Cup/disc ratio <0.5 • Clear disc rim	• Enlarged cup with cup/disc ratio >0.6 • Increase in cup size over time • Thinning of disc rim • Pale disc (optic nerve atrophy)

Zoom In Zoom Out Reset Add To Flash Card

1
2
3
4
5
6
7
8
9
10
11
12
13
14
15
16
17
18
19
20
21

Exhibit Display

Central retinal artery occlusion

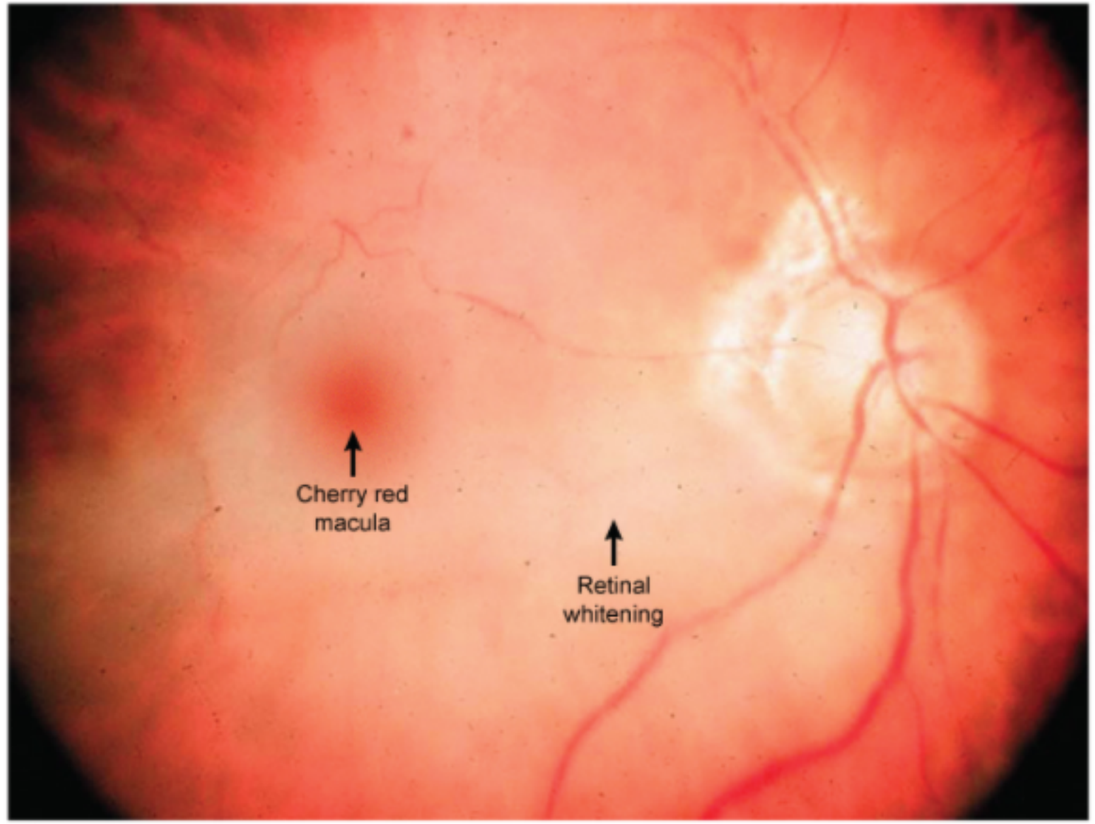

©UWorld

Zoom In
Zoom Out
Reset
Add To Flash Card

ENG
9:29 PM
7/10/2020

1
2
3
4
5
6
7
8
9
10
11
12
13
14
15
16
17
18
19
20
21

A 34-year-old woman comes to the physician complaining of double vision. She first experienced difficulty focusing her eyes while at work yesterday. Upon waking up this morning, her symptoms had progressed to frank diplopia. Her past medical history is insignificant. A complete physical examination is performed, including a full neurologic assessment. Shining light into her right eye causes constriction of her right pupil, but not the left pupil. Shining light into her left eye causes constriction of only her right pupil. Which of the following additional physical examination findings is likely to be found in this patient?

A. Absence of the left corneal reflex

B. Drooping of the left eyelid

C. Inability to close the left eye

D. Inward deviation of the left eye

E. Visual loss in the left eye

Submit

ENG
9:29 PM
7/10/2020

A 34-year-old woman comes to the physician complaining of double vision. She first experienced difficulty focusing her eyes while at work yesterday. Upon waking up this morning, her symptoms had progressed to frank diplopia. Her past medical history is insignificant. A complete physical examination is performed, including a full neurologic assessment. Shining light into her right eye causes constriction of her right pupil, but not the left pupil. Shining light into her left eye causes constriction of only her right pupil. Which of the following additional physical examination findings is likely to be found in this patient?

- A. Absence of the left corneal reflex (17%)
- ✓ B. Drooping of the left eyelid (60%)
- C. Inability to close the left eye (3%)
- D. Inward deviation of the left eye (10%)
- E. Visual loss in the left eye (8%)

Omitted
Correct answer
B

60%
Answered correctly

02 secs
Time Spent

06/14/2020
Last Updated

Explanation

Pupillary light reflex

1
2
3
4
5
6
7
8
9
10
11
12
13
14
15
16
17
18
19
20
21

Pupillary light reflex

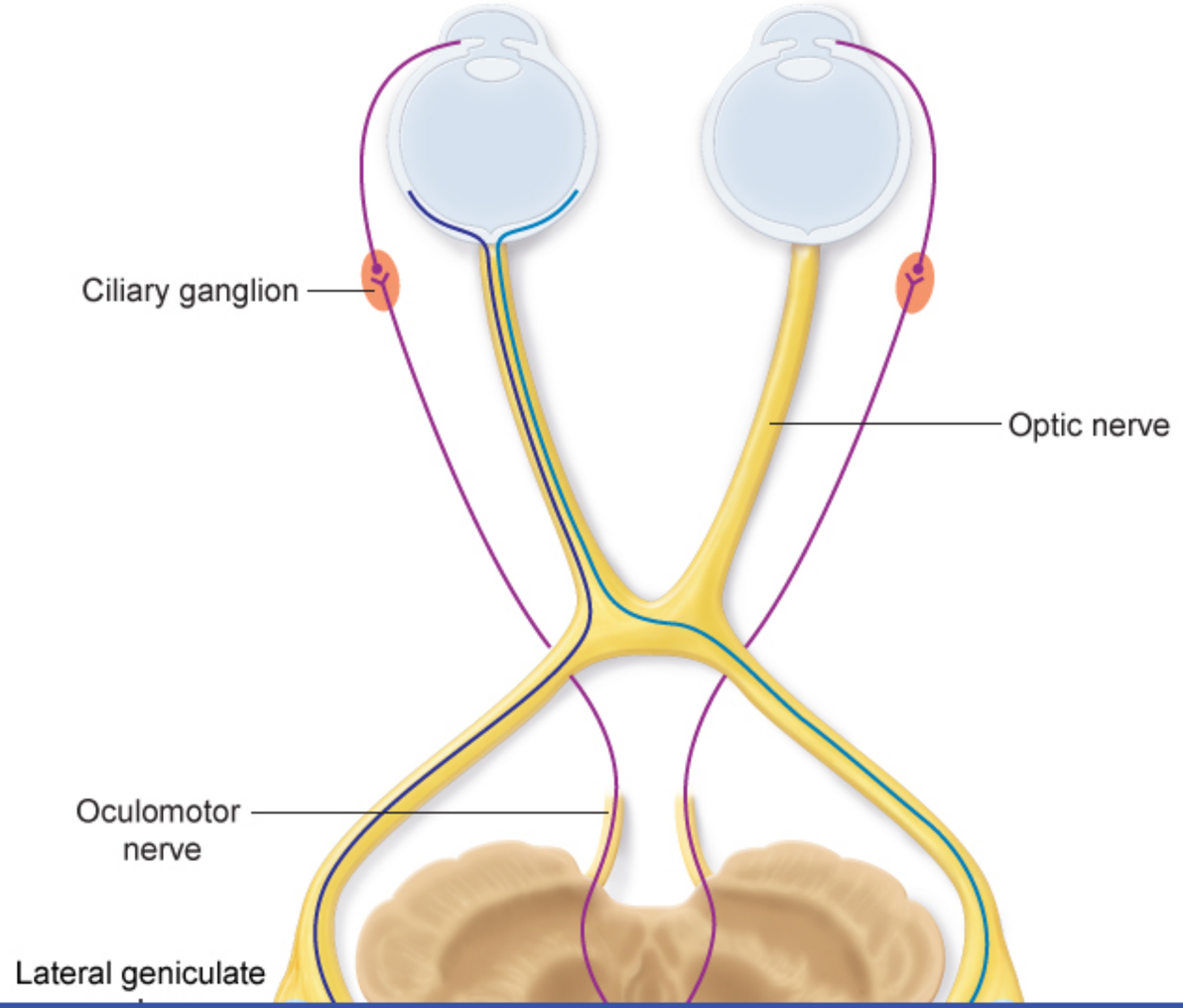

ENG
9:29 PM
7/10/2020

1
2
3
4
5
6
7
8
9
10
11
12
13
14
15
16
17
18
19
20
21

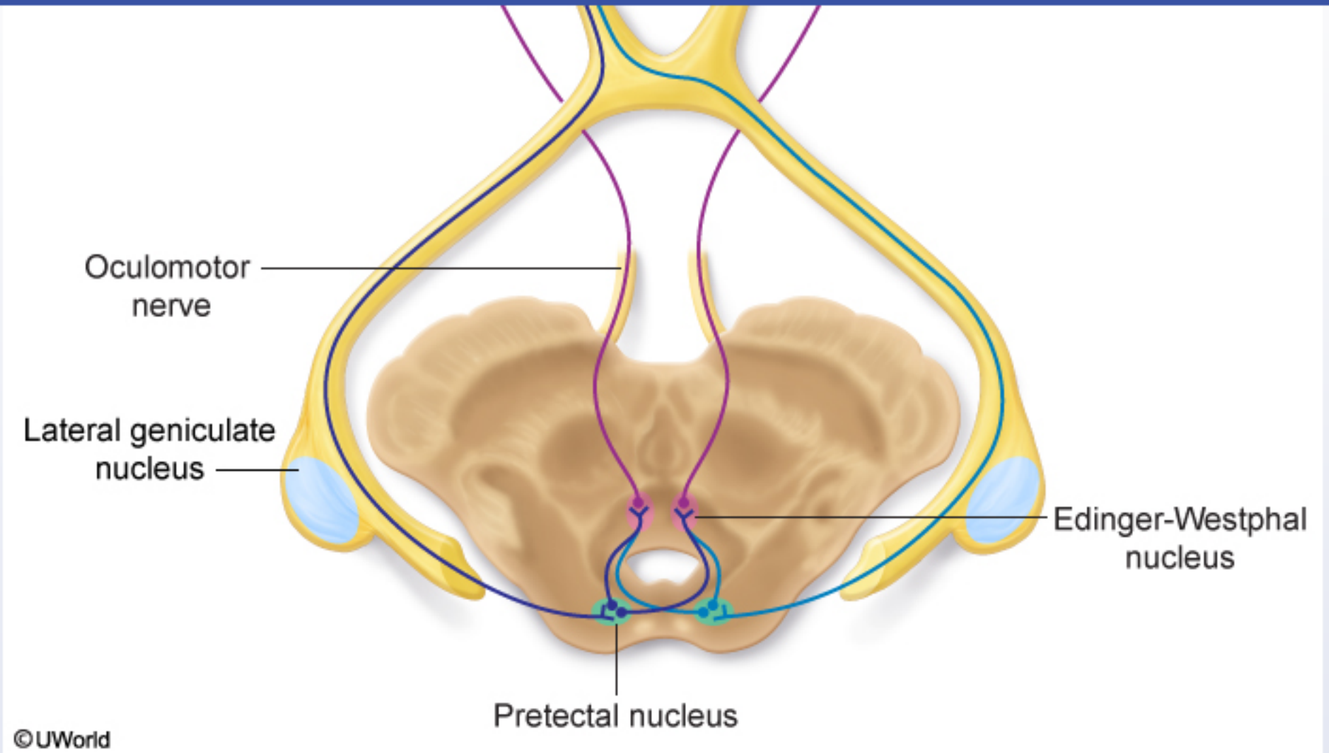

The pupillary light reflex is assessed by shining light in an eye and observing the response in that eye (direct) as well as the opposite eye (consensual). The optic nerve (CN II) is responsible for the afferent limb of this reflex; the oculomotor nerve (CN III) is responsible for the efferent limb. In this patient, the right CN II and right CN III are functional as there was a direct response seen when light was shined into the right eye. In addition, the left CN II is also functional as a consensual response occurred when light was shined into the left eye. However, constriction of the left pupil was not seen in either circumstance. Thus, this patient's lesion most likely involves her left CN III.

The symptoms of CN III palsy relate to the function of CN III:

1. A somatic component innervates the inferior, superior, and medial rectus; inferior oblique; and levator palpebrae muscles. Ptosis occurs due to paralysis of the levator palpebrae, and the unopposed action of the lateral rectus (CN VI) and superior oblique (CN IV) muscles leads to a

ENG
9:29 PM
7/10/2020

Pretectal nucleus

©UWorld

The pupillary light reflex is assessed by shining light in an eye and observing the response in that eye (direct) as well as the opposite eye (consensual). The optic nerve (CN II) is responsible for the afferent limb of this reflex; the oculomotor nerve (CN III) is responsible for the efferent limb. In this patient, the right CN II and right CN III are functional as there was a direct response seen when light was shined into the right eye. In addition, the left CN II is also functional as a consensual response occurred when light was shined into the left eye. However, constriction of the left pupil was not seen in either circumstance. Thus, this patient's lesion most likely involves her left CN III.

The symptoms of CN III palsy relate to the function of CN III:

1. A somatic component innervates the inferior, superior, and medial rectus; inferior oblique; and levator palpebrae muscles. Ptosis occurs due to paralysis of the levator palpebrae, and the unopposed action of the lateral rectus (CN VI) and superior oblique (CN IV) muscles leads to a "down-and-out" gaze.
2. Parasympathetic fibers of CN III innervate the iris sphincter and ciliary muscle. Paralysis of these fibers causes a fixed, dilated pupil and loss of accommodation.

CN III palsy can result from lesions anywhere along the nerve's path from the oculomotor nucleus in the midbrain to the extraocular muscles within the orbit. The most dreaded cause of isolated acute third nerve palsy is an actively enlarging intracranial aneurysm (at risk of imminent rupture).

(Choice A) Absence of the corneal reflex can result from lesions involving CN V_1 (afferent limb) or CN VII (efferent limb).

(Choice C) A lesion involving the left CN VII would result in inability to close the left eye.

(Choice D) Inward deviation of the left eye would result from a CN VI lesion and the resultant unopposed action of CN III.

(Choice E) The left CN II is functional as it was able to produce a consensual response in the right eye.

Educational objective:
The pupillary light reflex is assessed by shining light in an eye and observing the response in that eye (direct) and the opposite eye (consensual). The optic nerve (CN II) is responsible for the afferent limb of the pupillary reflex, and the oculomotor nerve (CN III) is responsible for the efferent limb.

left pupil was not seen in either circumstance. Thus, this patient's lesion most likely involves her left CN III.

The symptoms of CN III palsy relate to the function of CN III:

1. A somatic component innervates the inferior, superior, and medial rectus; inferior oblique; and levator palpebrae muscles. Ptosis occurs due to paralysis of the levator palpebrae, and the unopposed action of the lateral rectus (CN VI) and superior oblique (CN IV) muscles leads to a "down-and-out" gaze.
2. Parasympathetic fibers of CN III innervate the iris sphincter and ciliary muscle. Paralysis of these fibers causes a fixed, dilated pupil and loss of accommodation.

CN III palsy can result from lesions anywhere along the nerve's path from the oculomotor nucleus in the midbrain to the extraocular muscles within the orbit. The most dreaded cause of isolated acute third nerve palsy is an actively enlarging intracranial aneurysm (at risk of imminent rupture).

(Choice A) Absence of the corneal reflex can result from lesions involving CN V_1 (afferent limb) or CN VII (efferent limb).

(Choice C) A lesion involving the left CN VII would result in inability to close the left eye.

(Choice D) Inward deviation of the left eye would result from a CN VI lesion and the resultant unopposed action of CN III.

(Choice E) The left CN II is functional as it was able to produce a consensual response in the right eye.

Educational objective:
The pupillary light reflex is assessed by shining light in an eye and observing the response in that eye (direct) and the opposite eye (consensual). The optic nerve (CN II) is responsible for the afferent limb of the pupillary reflex, and the oculomotor nerve (CN III) is responsible for the efferent limb.

Anatomy	Ophthalmology	Cranial nerve palsy
Subject	System	Topic

Copyright © UWorld. All rights reserved.

ENG
9:29 PM
7/10/2020

A 14-year-old boy is brought to the clinic by his mother due to changes in vision. For the last few weeks, the patient has been squinting when trying to read the interactive whiteboard in class and has had to sit closer to the front of the room. He has also developed headaches. The patient has no chronic medical conditions and takes no medications. Temperature is 37.2 C (99 F), blood pressure is 116/76 mm Hg, and pulse is 70/min. Examination of the eyes shows equal and reactive pupils. Extraocular muscles are intact, and visual field testing reveals no defects. Visual acuity shows 20/70 in both eyes. His ability to read close text is normal. Which of the following is the most likely cause of this patient's symptoms?

A. Chronically increased intraocular pressure

B. Disturbance in development of the visual cortex

C. Increased anterior-posterior diameter of the eyes

D. Loss of accommodating power of the lens

E. Refracted image focused posterior to the retina

Submit

A 14-year-old boy is brought to the clinic by his mother due to changes in vision. For the last few weeks, the patient has been squinting when trying to read the interactive whiteboard in class and has had to sit closer to the front of the room. He has also developed headaches. The patient has no chronic medical conditions and takes no medications. Temperature is 37.2 C (99 F), blood pressure is 116/76 mm Hg, and pulse is 70/min. Examination of the eyes shows equal and reactive pupils. Extraocular muscles are intact, and visual field testing reveals no defects. Visual acuity shows 20/70 in both eyes. His ability to read close text is normal. Which of the following is the most likely cause of this patient's symptoms?

A. Chronically increased intraocular pressure (2%)

B. Disturbance in development of the visual cortex (0%)

✓ C. Increased anterior-posterior diameter of the eyes (54%)

D. Loss of accommodating power of the lens (7%)

E. Refracted image focused posterior to the retina (35%)

Omitted
Correct answer
C

54%
Answered correctly

01 sec
Time Spent

03/30/2020
Last Updated

Explanation

This patient with decreased visual acuity and an otherwise normal ophthalmic examination likely has simple **myopia (nearsightedness)**, a **refractive error** caused by an **increased anterior-posterior diameter** of the eye. The risk is greatest for those with a positive family history or

1
2
3
4
5
6
7
8
9
10
11
12
13
14
15
16
17
18
19
20
21

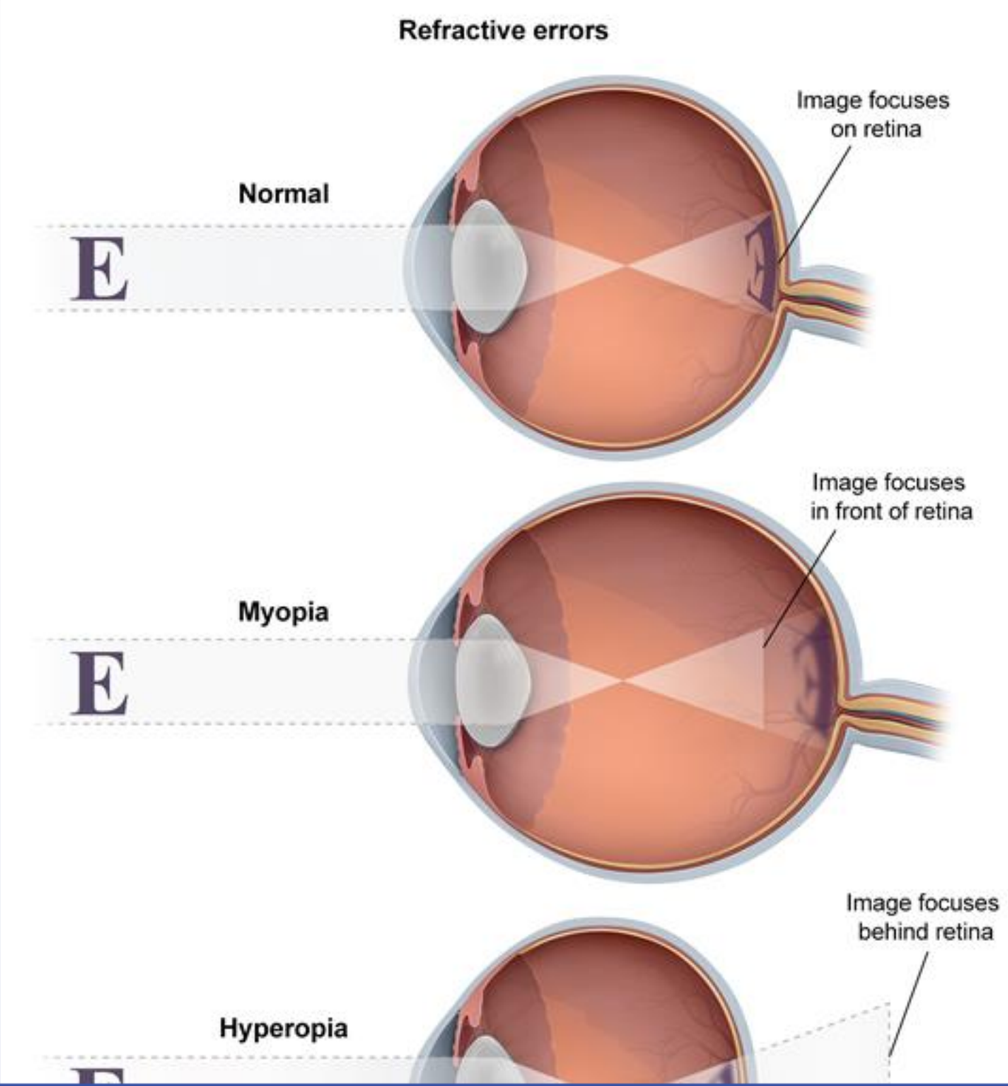

ENG
9:29 PM
7/10/2020

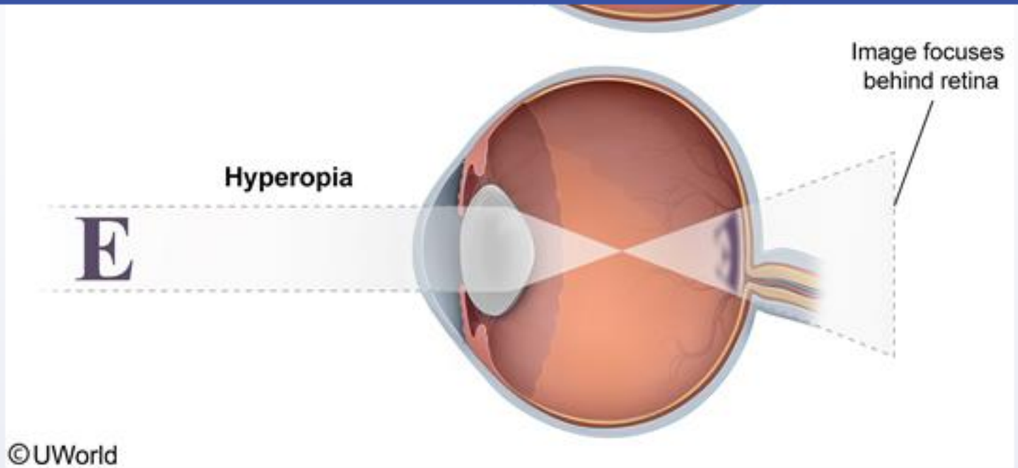

This patient with decreased visual acuity and an otherwise normal ophthalmic examination likely has simple **myopia (nearsightedness)**, a **refractive error** caused by an **increased anterior-posterior diameter** of the eye. The risk is greatest for those with a positive family history or those of East Asian descent.

During the adolescent growth spurt, the axial length of the globe also grows rapidly, making the incidence of new-onset myopia highest in this age group. As the anterior-posterior diameter increases, the focal point of a **refracted image lies anterior to the retina**. For images to be seen clearly, they must be projected directly onto the retina; therefore, the image displacement in myopia causes **blurred vision** of **long-distance** objects and decreased visual acuity on examination. **Vision** of **nearby** objects is unaffected and appears **clear** in myopic patients. The remainder of the examination, including extraocular movements, peripheral field testing, and funduscopic examination, is normal.

Management is with prescription glasses with a diverging (concave) lens, which refocuses the refracted image onto the retina. The degree of myopia usually stabilizes by early adulthood.

(Choice A) Glaucoma, most commonly due to chronically elevated intraocular pressure, is characterized by optic neuropathy, as evidenced by optic cupping seen on funduscopic examination. Visual acuity may be affected but is a late manifestation after progressive loss of peripheral vision, which is normal in this patient.

group. As the anterior-posterior diameter increases, the focal point of a **refracted image lies anterior to the retina**. For images to be seen clearly, they must be projected directly onto the retina; therefore, the image displacement in myopia causes **blurred vision** of **long-distance** objects and decreased visual acuity on examination. **Vision** of **nearby** objects is unaffected and appears **clear** in myopic patients. The remainder of the examination, including extraocular movements, peripheral field testing, and funduscopic examination, is normal.

Management is with prescription glasses with a diverging (concave) lens, which refocuses the refracted image onto the retina. The degree of myopia usually stabilizes by early adulthood.

(Choice A) Glaucoma, most commonly due to chronically elevated intraocular pressure, is characterized by optic neuropathy, as evidenced by optic cupping seen on funduscopic examination. Visual acuity may be affected but is a late manifestation after progressive loss of peripheral vision, which is normal in this patient.

(Choice B) Untreated strabismus (misalignment of the eyes) in early childhood can cause unilateral visual cortex suppression to avoid diplopia and eventually lead to amblyopia (decreased visual acuity). This patient's recent symptom onset and normal extraocular movements make this diagnosis unlikely.

(Choice D) Presbyopia is a nonrefractive error that increases with age due to the loss of accommodating power of the lens from decreased elasticity. Blurry vision of nearby objects typically develops in patients age >40.

(Choice E) Hyperopia (farsightedness) is a refractive error characterized by a reduced anterior-posterior diameter of the eye, causing the focal point of the refracted image to be positioned posterior to the retina. In contrast to myopia, hyperopia causes blurred vision of nearby objects and is corrected by a converging (convex) lens.

Educational objective:
Myopia (nearsightedness) is a refractive error in which the focal point of an image falls anterior to the retina due to an increased anterior-posterior diameter of the eyes. Patients have difficulty seeing objects at a distance and have normal near vision.

References

- Childhood myopia: epidemiology, risk factors, and prevention.
- Prevention of progression in myopia: a systematic review.

1
2
3
4
5
6
7
8
9
10
11
12
13
14
15
16
17
18
19
20
21

group. As the anterior-posterior diameter increases, the focal point of a **refracted image lies anterior to the retina**. For images to be seen

Exhibit Display

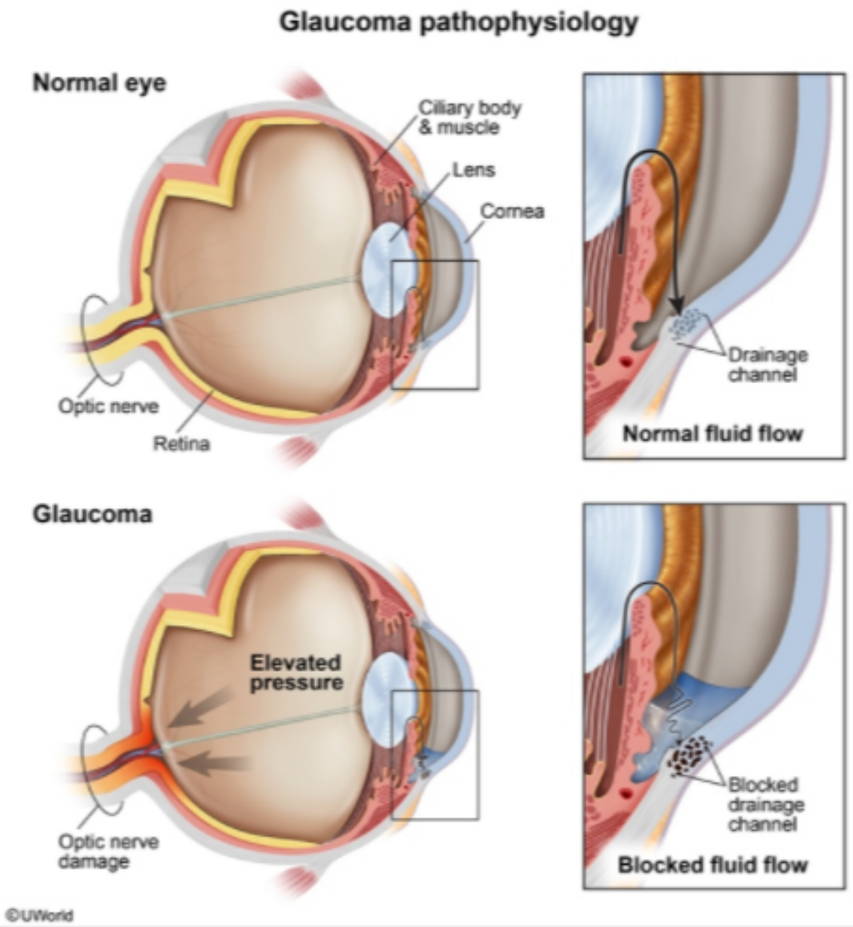

Zoom In Zoom Out Reset Add To Flash Card

- Prevention of progression in myopia: a systematic review.

ENG 9:30 PM 7/10/2020

1
2
3
4
5
6
7
8
9
10
11
12
13
14
15
16
17
18
19
20
21

group. As the anterior-posterior diameter increases, the focal point of a **refracted image lies anterior to the retina**. For images to be seen

Exhibit Display

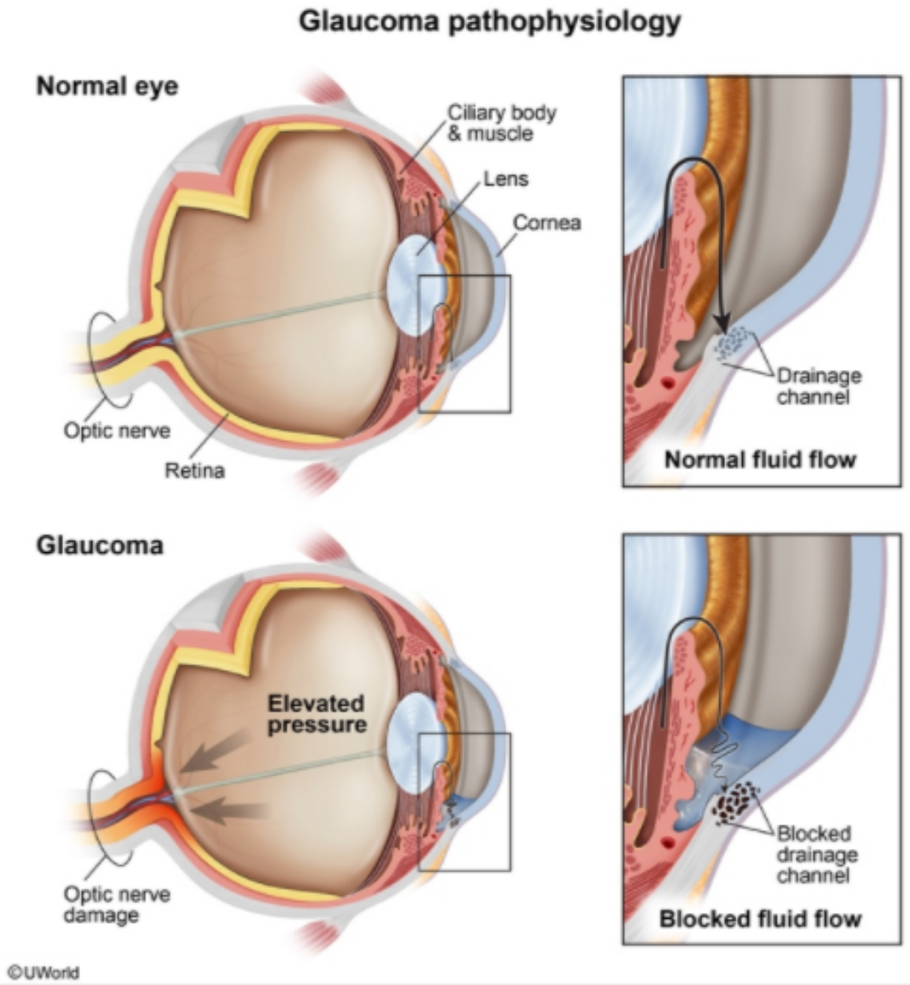

Zoom In Zoom Out Reset Add To Flash Card

- The science behind myopia

group. As the anterior-posterior diameter increases, the focal point of a **refracted image lies anterior to the retina**. For images to be seen

Exhibit Display

Strabismus

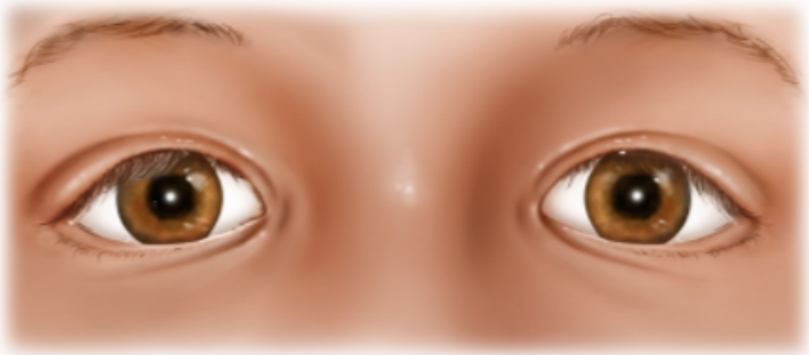

Normal eyes

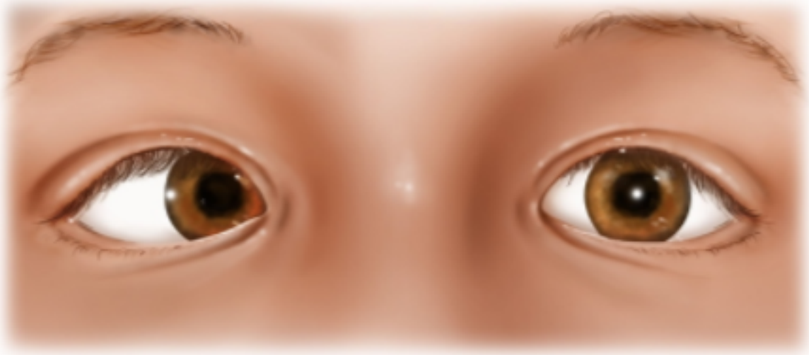

Esotropia (strabismus)

©UWorld

Zoom In Zoom Out Reset Add To Flash Card

- The science behind myopia

group. As the anterior-posterior diameter increases, the focal point of a **refracted image lies anterior to the retina**. For images to be seen

Exhibit Display

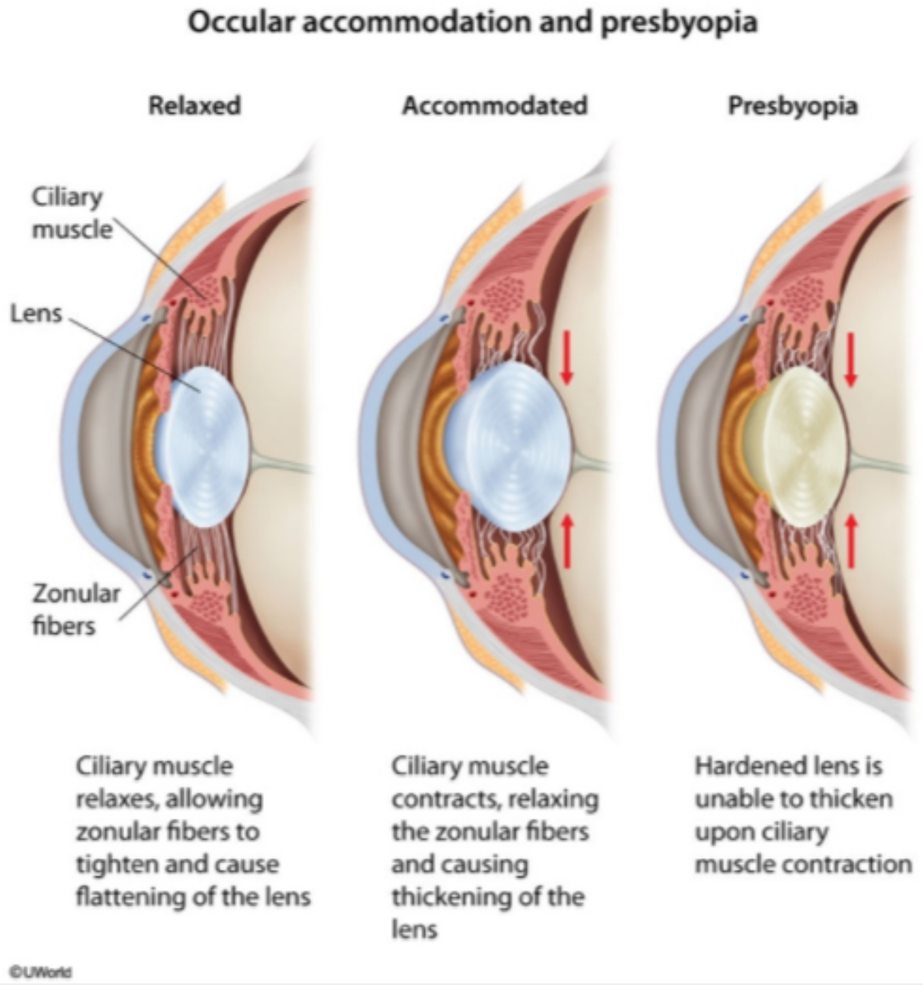

Zoom In Zoom Out Reset Add To Flash Card

- The science behind myopia

group. As the anterior-posterior diameter increases, the focal point of a **refracted image lies anterior to the retina**. For images to be seen

Exhibit Display

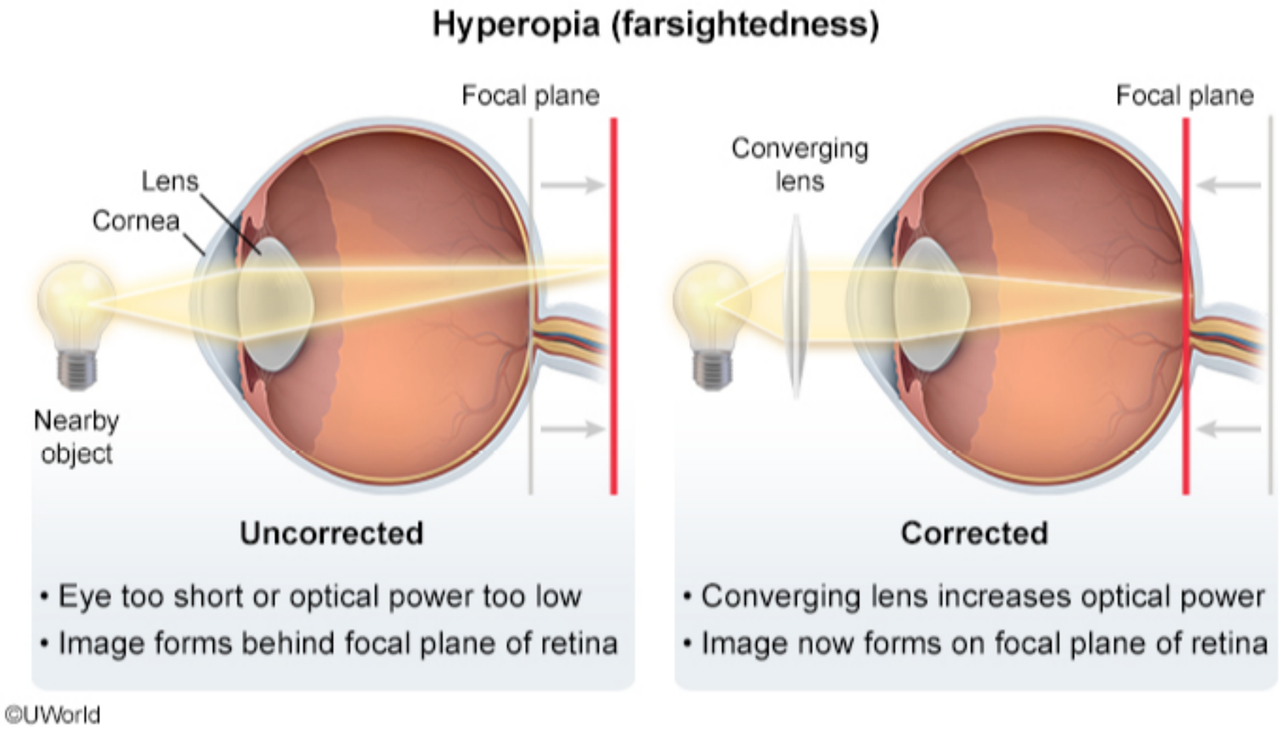

Zoom In Zoom Out Reset Add To Flash Card

- The science behind myopia

A 68-year-old woman is evaluated for vision impairment. The patient has a decrease in both distant and near vision and has had occasional floaters. She has had no pain or redness in her eyes, headache, focal weakness, or sensory loss. Medical history is notable for type 2 diabetes mellitus, hypertension, and chronic kidney disease. Blood pressure is 138/84 mm Hg and pulse is 76/min. The pupils are equal and reactive to light bilaterally. Anterior chambers are clear, and there are no opacities of the cornea or lens. Funduscopic examination reveals scattered retinal microaneurysms, dot-and-blot hemorrhages, and cotton-wool spots, as well as new blood vessel formation. Which of the following contributed most to the pathogenesis of this patient's current ocular condition?

A. Age-related degeneration of retinal pigment epithelium

B. Chronic hyperglycemia-induced microvascular injury

C. Ganglion cell death due to high intraocular pressure

D. Retinal arterial occlusion from atherosclerotic disease

E. Vascular injury from increased intraluminal pressure

Submit

A 68-year-old woman is evaluated for vision impairment. The patient has a decrease in both distant and near vision and has had occasional floaters. She has had no pain or redness in her eyes, headache, focal weakness, or sensory loss. Medical history is notable for type 2 diabetes mellitus, hypertension, and chronic kidney disease. Blood pressure is 138/84 mm Hg and pulse is 76/min. The pupils are equal and reactive to light bilaterally. Anterior chambers are clear, and there are no opacities of the cornea or lens. Funduscopic examination reveals scattered retinal microaneurysms, dot-and-blot hemorrhages, and cotton-wool spots, as well as new blood vessel formation. Which of the following contributed most to the pathogenesis of this patient's current ocular condition?

- A. Age-related degeneration of retinal pigment epithelium (3%)
- ✓ B. Chronic hyperglycemia-induced microvascular injury (72%)
- C. Ganglion cell death due to high intraocular pressure (0%)
- D. Retinal arterial occlusion from atherosclerotic disease (6%)
- E. Vascular injury from increased intraluminal pressure (16%)

Omitted
Correct answer
B

72%
Answered correctly

02 secs
Time Spent

02/17/2020
Last Updated

Explanation

Diabetic retinopathy, proliferative (PDR)

Diabetic retinopathy, proliferative (PDR)

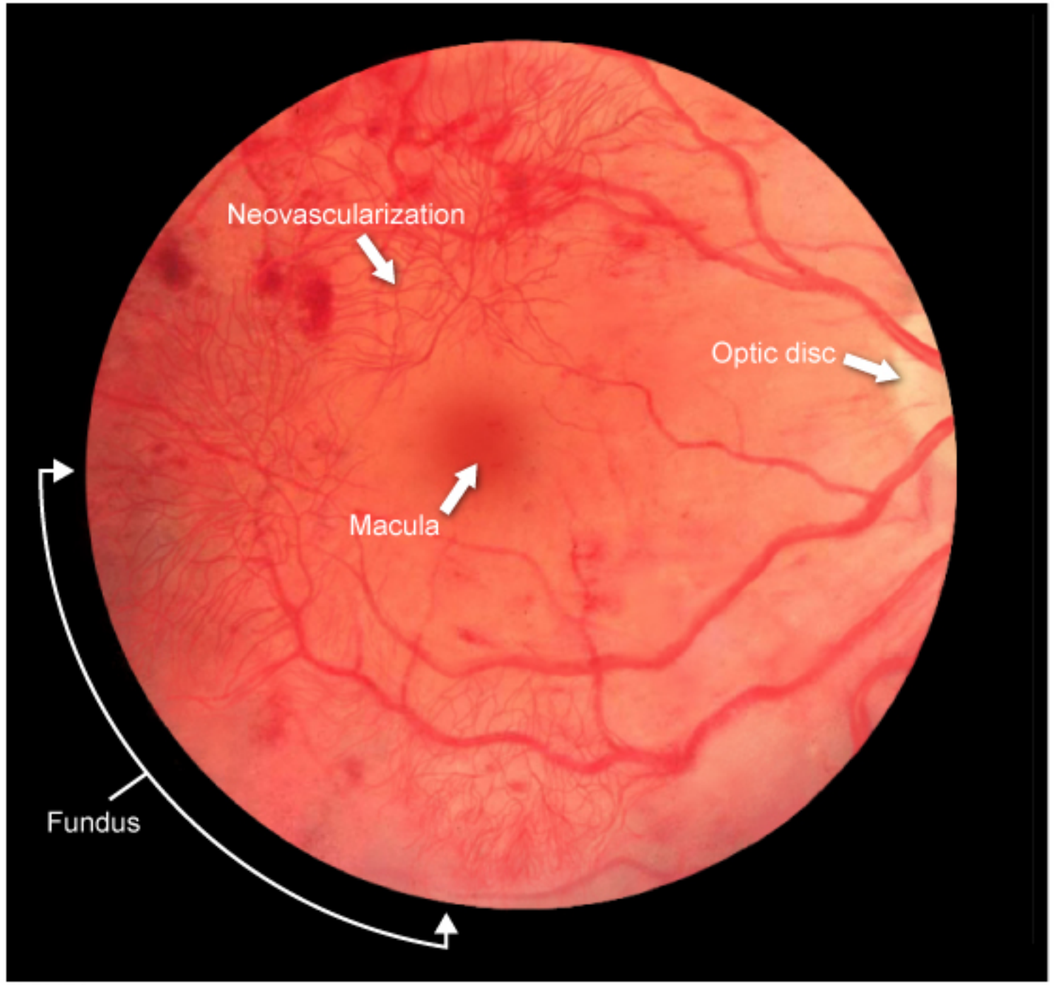

©UWorld

This patient, with painless vision loss and retinal neovascularization, has proliferative **diabetic retinopathy** (DR). DR is a result of chronic hyperglycemic injury to the small retinal vessels and is considered a **microangiopathic** complication of diabetes (along with neuropathy and nephropathy). The prevalence of DR is proportionate to the duration of diabetes and severity of hyperglycemia over time; tight control of diabetes

©UWorld

This patient, with painless vision loss and retinal neovascularization, has proliferative **diabetic retinopathy** (DR). DR is a result of chronic hyperglycemic injury to the small retinal vessels and is considered a **microangiopathic** complication of diabetes (along with neuropathy and nephropathy). The prevalence of DR is proportionate to the duration of diabetes and severity of hyperglycemia over time; tight control of diabetes is associated with a lower long-term risk of DR.

DR is categorized as follows:

- **Nonproliferative** (early disease): The earliest morphologic changes include thickening of the basement membrane and failure of the blood-retinal barrier. Increased permeability allows leakage of fluid into the retina (macular edema), which can distort vision and leave behind lipid-rich deposits (hard exudates). Arteriolar obstruction causes ischemic injury to the retina, which manifests as cotton-wool spots. Other findings include microaneurysms and dot-blot hemorrhages (due to microaneurysm rupture).
- **Proliferative** (advanced disease): Progressive retinal ischemia stimulates production of angiogenic factors (eg, vascular endothelial growth factor), leading to formation of new retinal vessels (**neovascularization**). The new vessels are fragile and often extend into the adjacent vitreous. Traction from the vitreous can cause detachment of the retina or laceration of the vessels, leading to acute hemorrhage and vision loss.

(Choice A) Age-related macular degeneration presents with slowly progressive *central vision* loss. It is due to oxidative damage to the pigment epithelium and choriocapillaris with abnormal extracellular matrix formation (drusen). In late-stage disease, patients may develop neovascularization ("wet" macular degeneration), but associated findings include subretinal drusen and pigment abnormalities.

(Choice C) Open-angle glaucoma is a form of optic neuropathy, characterized by ganglion cell death in association with elevated intraocular pressure. It causes insidious loss of *peripheral vision*; examination findings include enlargement of the retinal cup and a pale optic disc with thinning of the rim.

(Choice D) Atheroembolic retinal artery occlusion presents with acute *monocular* vision loss. Examination findings include retinal pallor and a cherry red spot at the macula.

(Choice E) Hypertensive retinopathy can manifest with retinal hemorrhages, cotton-wool spots, and hard exudates. However, the thickened and stiffened arterial walls are typically visible as arteriolar narrowing and impingement on the veins where they are crossed by arteries (arteriovenous nicking).

findings include microaneurysms and dot-blot hemorrhages (due to microaneurysm rupture).

- **Proliferative** (advanced disease): Progressive retinal ischemia stimulates production of angiogenic factors (eg, vascular endothelial growth factor), leading to formation of new retinal vessels (**neovascularization**). The new vessels are fragile and often extend into the adjacent vitreous. Traction from the vitreous can cause detachment of the retina or laceration of the vessels, leading to acute hemorrhage and vision loss.

(Choice A) Age-related macular degeneration presents with slowly progressive *central vision* loss. It is due to oxidative damage to the pigment epithelium and choriocapillaris with abnormal extracellular matrix formation (drusen). In late-stage disease, patients may develop neovascularization ("wet" macular degeneration), but associated findings include subretinal drusen and pigment abnormalities.

(Choice C) Open-angle glaucoma is a form of optic neuropathy, characterized by ganglion cell death in association with elevated intraocular pressure. It causes insidious loss of *peripheral vision*; examination findings include enlargement of the retinal cup and a pale optic disc with thinning of the rim.

(Choice D) Atheroembolic retinal artery occlusion presents with acute *monocular* vision loss. Examination findings include retinal pallor and a cherry red spot at the macula.

(Choice E) Hypertensive retinopathy can manifest with retinal hemorrhages, cotton-wool spots, and hard exudates. However, the thickened and stiffened arterial walls are typically visible as arteriolar narrowing and impingement on the veins where they are crossed by arteries (arteriovenous nicking).

Educational objective:
Chronic hyperglycemia in patients with diabetes can lead to increased permeability and arteriolar obstruction in retinal vessels. The resulting ischemia stimulates production of vascular endothelial growth factor and other angiogenic factors, leading to neovascularization (proliferative diabetic retinopathy). Complications include retinal hemorrhage, retinal detachment, and vision loss.

Pathology	Ophthalmology	Diabetic retinopathy
Subject	System	Topic

Copyright © UWorld. All rights reserved.

©UWorld

1
2
3
4
5
6
7
8
9
10
11
12
13
14
15
16
17
18
19
20
21

Exhibit Display

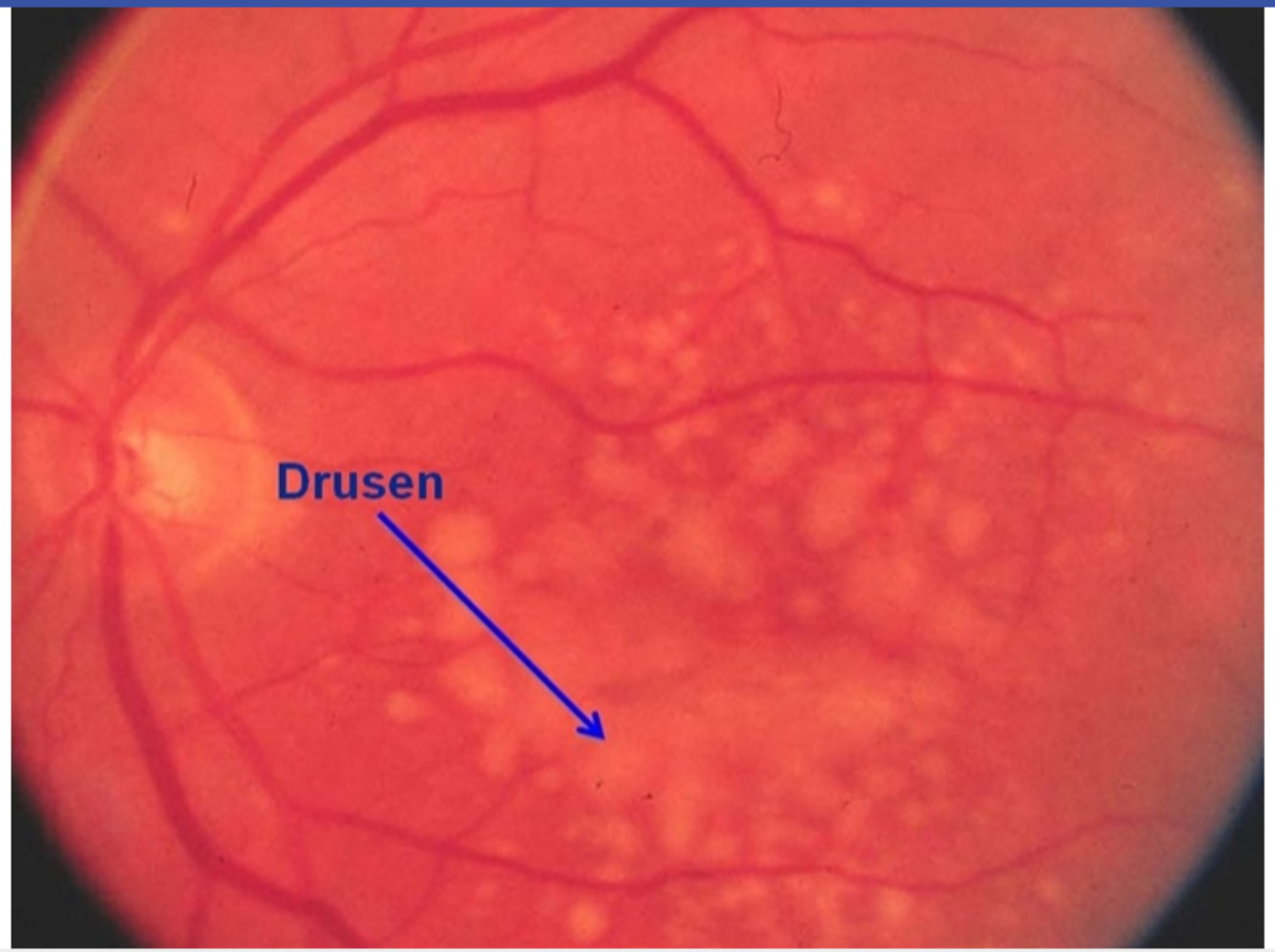

Zoom In | Zoom Out | Reset | Add To New Card | Existing Card

©UWorld

Exhibit Display

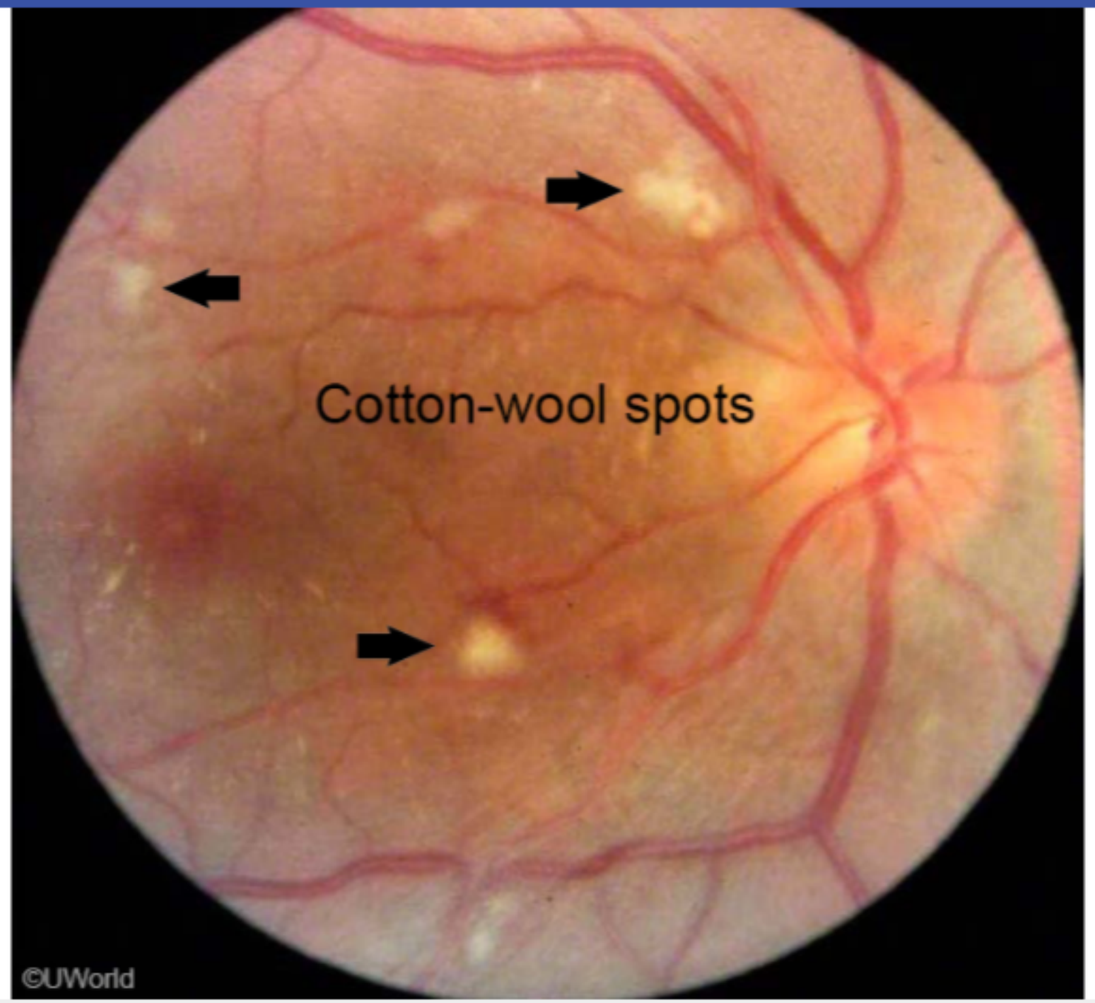

Zoom In | Zoom Out | Reset | Add To New Card | Existing Card

©UWorld

Exhibit Display

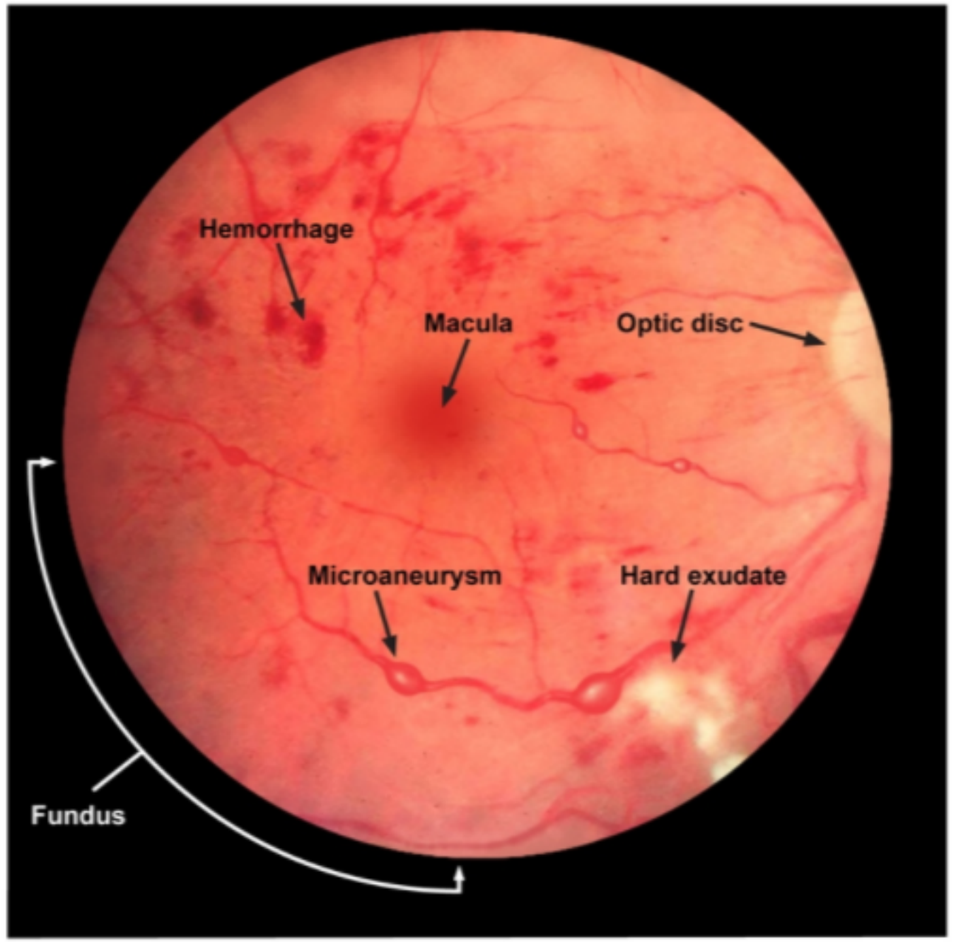

©UWorld

Zoom In | Zoom Out | Reset | Add To New Card | Existing Card

©UWorld

Exhibit Display

Optic disc in glaucoma

Normal	Open-angle glaucoma
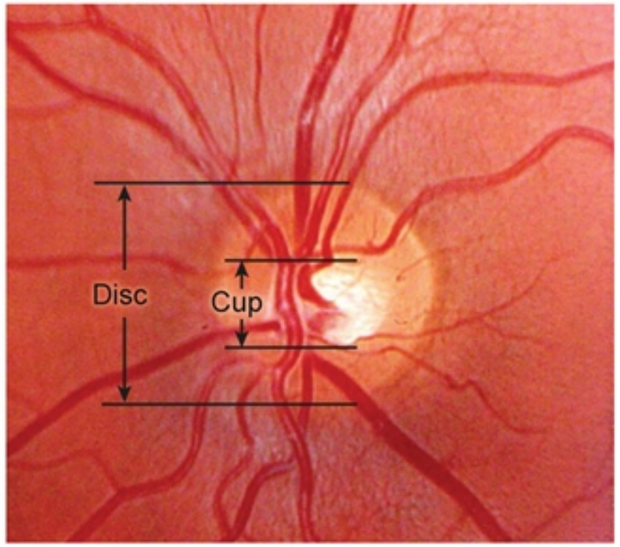	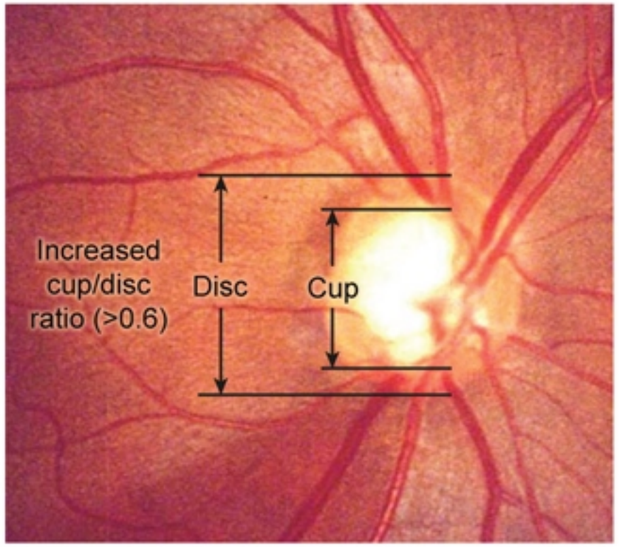
• Cup/disc ratio <0.5 • Clear disc rim	• Enlarged cup with cup/disc ratio >0.6 • Increase in cup size over time • Thinning of disc rim • Pale disc (optic nerve atrophy)

©UWorld

Zoom In | Zoom Out | Reset | Add To New Card | Existing Card

1
2
3
4
5
6
7
8
9
10
11
12
13
14
15
16
17
18
19
20
21

findings include microaneurysms and dot-blot hemorrhages (due to microaneurysm rupture).

Exhibit Display

Central retinal artery occlusion

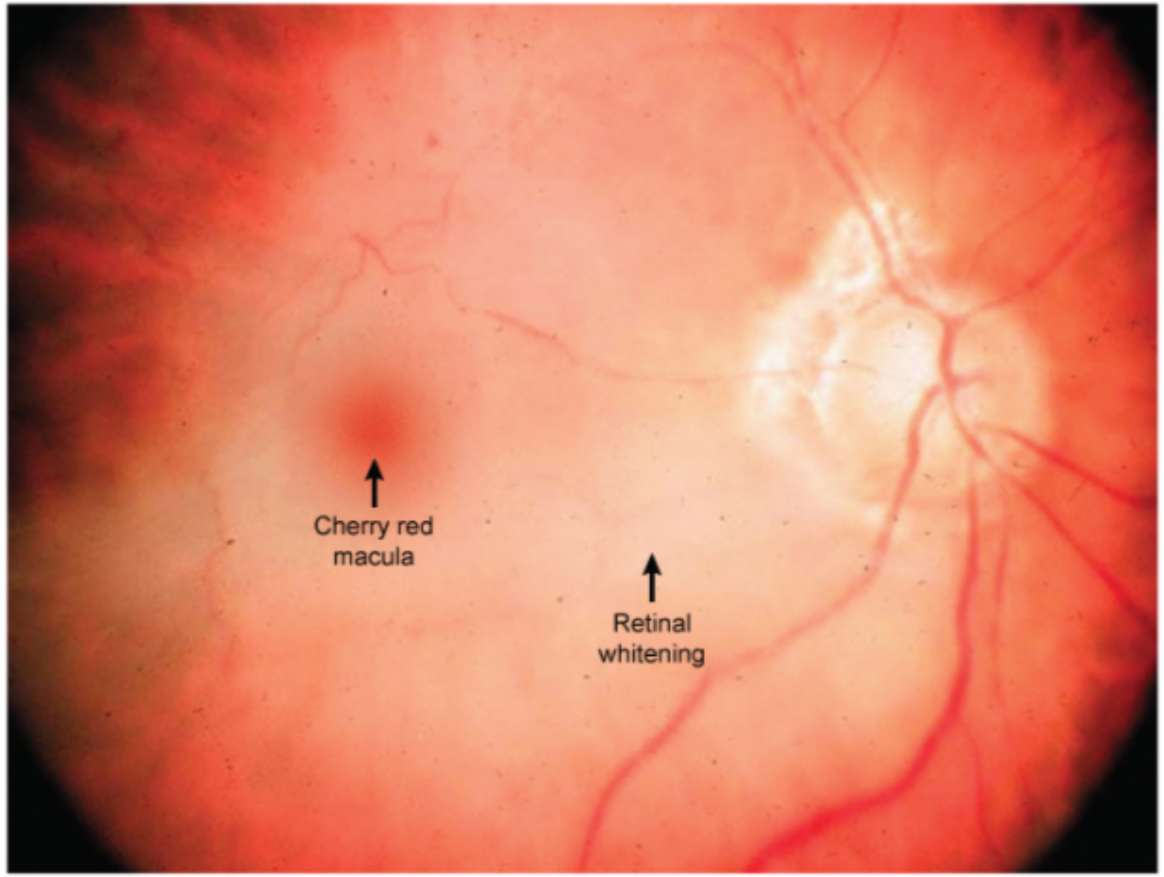

©UWorld

Zoom In | Zoom Out | Reset | Add To New Card | Existing Card

1
2
3
4
5
6
7
8
9
10
11
12
13
14
15
16
17
18
19
20
21

findings include microaneurysms and dot-blot hemorrhages (due to microaneurysm rupture).

Exhibit Display

Hypertensive retinopathy

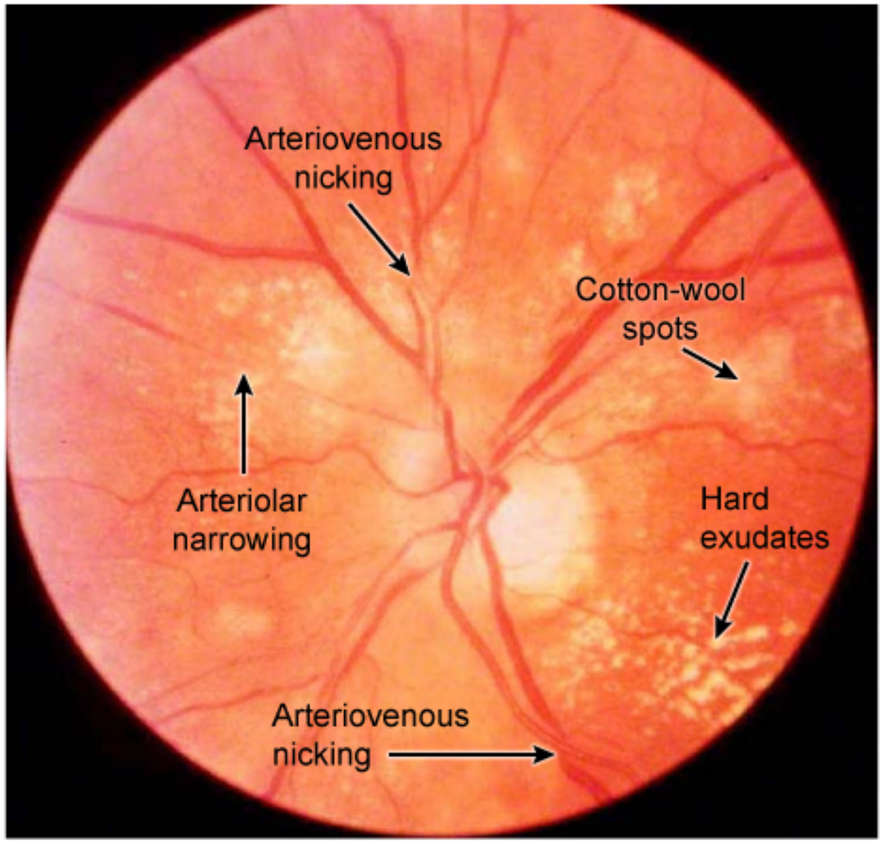

©UWorld

Zoom In | Zoom Out | Reset | Add To New Card | Existing Card

A 58-year-old airline captain comes to the office after he was found to have abnormal vision testing during a pilot medical certification examination. The patient feels well and has no ocular symptoms. Vision testing shows normal visual acuity but moderate loss of peripheral vision in both eyes. Results of the funduscopic examination are shown in the image below.

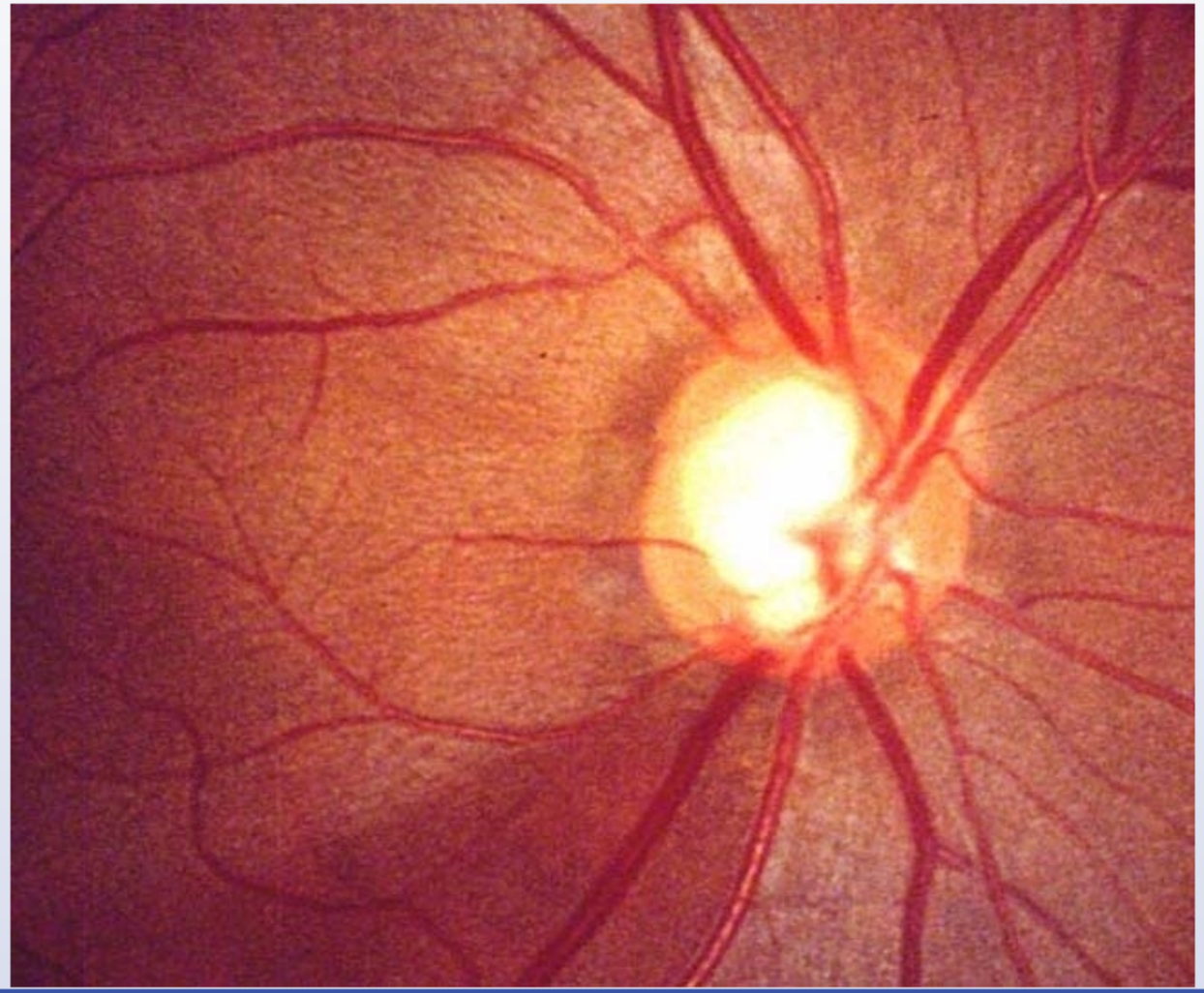

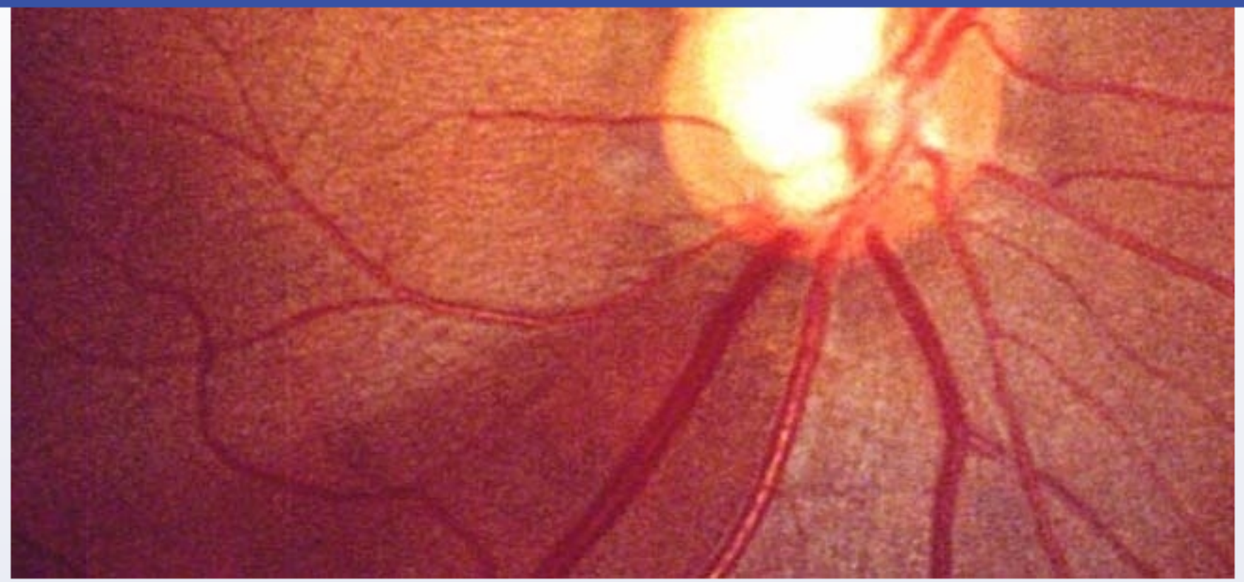

Other neurologic and cardiopulmonary examination findings are unremarkable. He is started on latanoprost eyedrops. The medication is most likely to improve this patient's condition through which of the following mechanisms?

A. Decreased bicarbonate formation in ciliary body

B. Decreased formation of abnormal blood vessels in retina

C. Decreased secretion of aqueous humor

D. Increased outflow of aqueous humor

E. Vasoconstriction in ciliary body

Submit

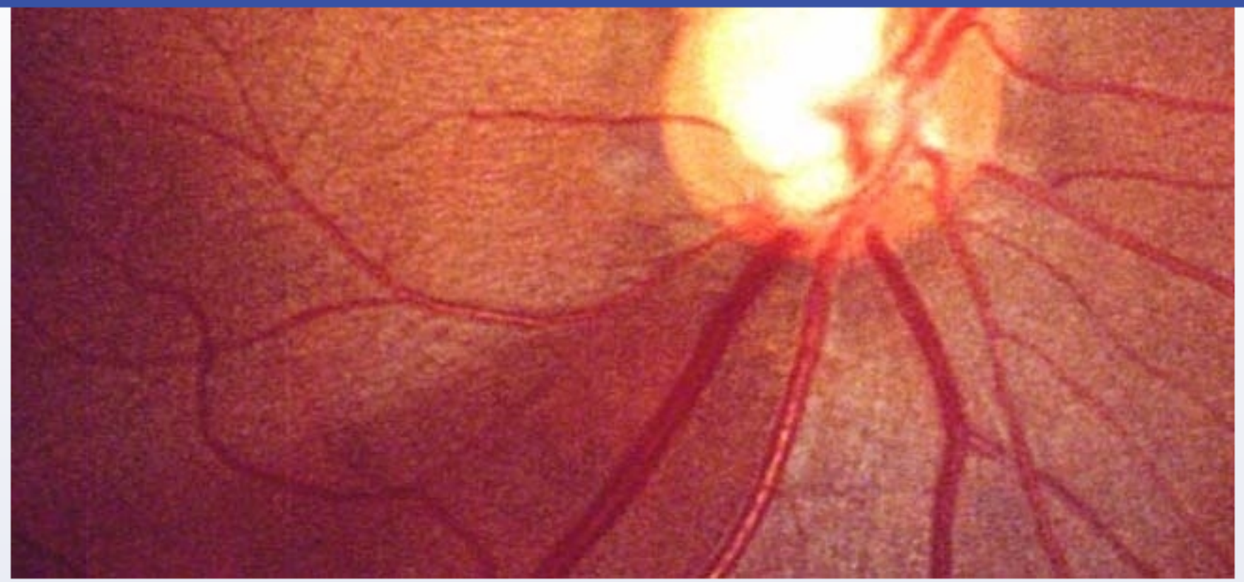

Other neurologic and cardiopulmonary examination findings are unremarkable. He is started on latanoprost eyedrops. The medication is most likely to improve this patient's condition through which of the following mechanisms?

- A. Decreased bicarbonate formation in ciliary body (2%)
- B. Decreased formation of abnormal blood vessels in retina (10%)
- C. Decreased secretion of aqueous humor (21%)
- ✓ D. Increased outflow of aqueous humor (61%)
- E. Vasoconstriction in ciliary body (4%)

Omitted
Correct answer

61%
Answered correctly

08 secs
Time Spent

04/02/2020
Last Updated

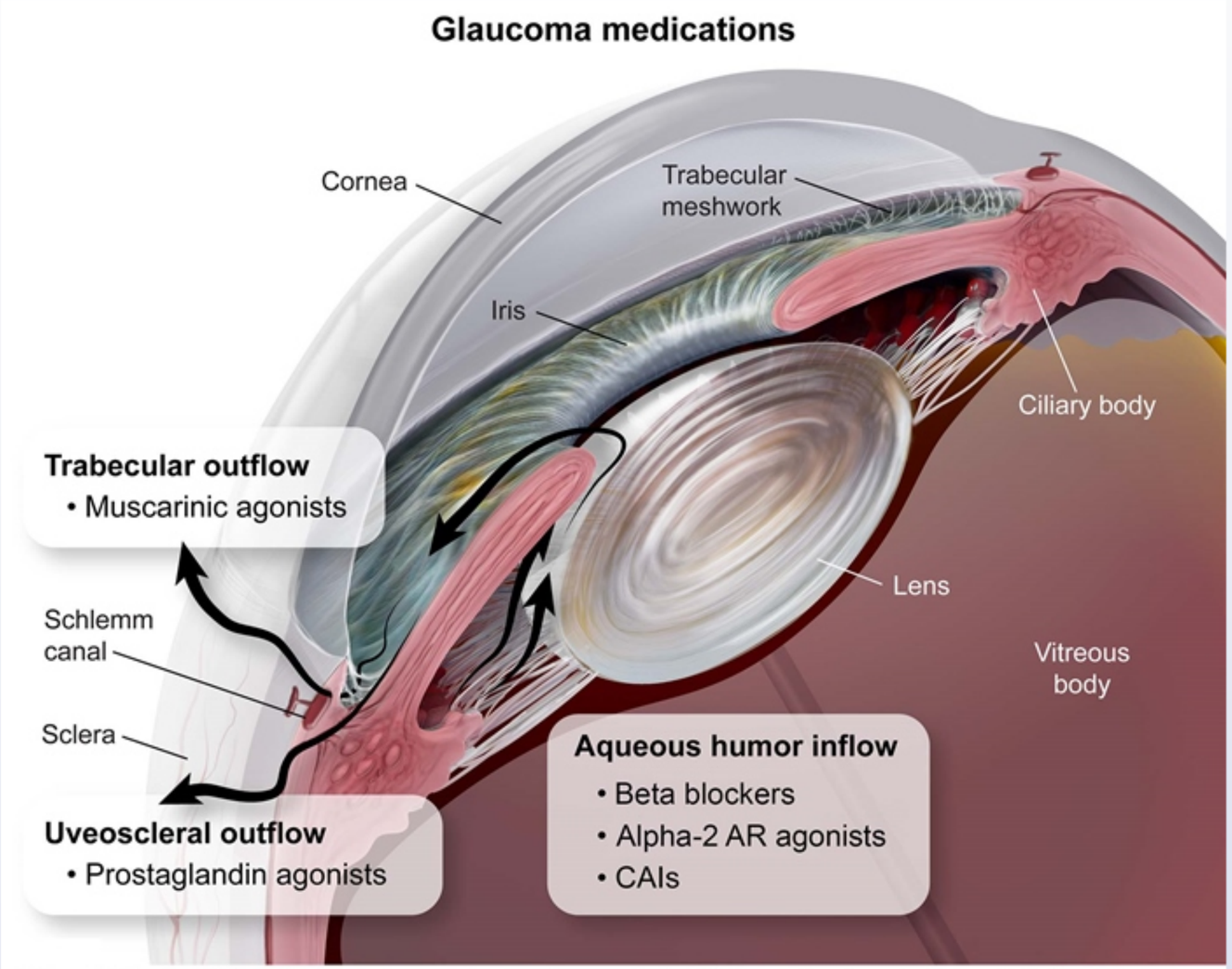

Alpha-2 AR agonists = alpha-2 adrenergic receptor agonists; **CAIs** = carbonic anhydrase inhibitors.

©UWorld

Aqueous humor is secreted by epithelial cells of the ciliary body into the posterior eye chamber. The fluid then flows through the pupil into the

©UWorld

Aqueous humor is secreted by epithelial cells of the ciliary body into the posterior eye chamber. The fluid then flows through the pupil into the anterior chamber to the iridocorneal angle. Here, it diffuses through a trabecular network into Schlemm's canal (scleral venous sinus) and subsequently drains into episcleral and conjunctival veins. A small amount of aqueous can also diffuse through the ciliary muscle and adjacent sclera (uveoscleral pathway).

Open-angle glaucoma is characterized by **increased intraocular pressure** due to increased secretion or decreased outflow of aqueous humor. It is a form of optic neuropathy and causes progressive loss of ganglion cell axons, which may be visualized as a pale optic disc and enlarged optic cup (compared to normal retina). Symptoms evolve over decades, with progressive loss of **peripheral visual fields**.

Glaucoma is managed with agents that either decrease production or increase outflow of aqueous humor. Latanoprost is a topical **prostaglandin** used in the treatment of glaucoma. It is applied as a prodrug and converted to the active form by esterases in the cornea. Prostaglandins are the preferred first-line agents for the treatment of glaucoma, and although the exact mechanism of action is uncertain, they have been found to decrease the collagen content in the uveoscleral outflow pathway and **increase outflow** of aqueous humor. They are also known to cause increased pigmentation in the iris and eyelashes.

(Choices A, C, and E) Carbonic anhydrase inhibitors (eg, dorzolamide) decrease formation of bicarbonate in the ciliary body, leading to decreased sodium and fluid transport and subsequently decreased production of aqueous humor. Alpha-adrenergic agonists (eg, brimonidine) inhibit production of aqueous humor due to vasoconstriction in the ciliary body. Beta blockers (eg, timolol) also decrease production of aqueous humor. Prostaglandins do not affect production of aqueous humor but are often used in combination with these other agents.

(Choice B) Increased formation of new blood vessels at the optic disc is the characteristic feature of proliferative diabetic retinopathy. Strict control of diabetes will reduce the risk of diabetic retinopathy, but it is not affected by topical prostaglandins.

Educational objective:
Glaucoma is a form of optic neuropathy characterized by increased intraocular pressure associated with increased production or decreased outflow of aqueous humor. Topical prostaglandins (eg, latanoprost) increase outflow of aqueous via the uveoscleral pathway and are the preferred treatment for open-angle glaucoma.

References

- Latanoprost ophthalmic solution in the treatment of open angle glaucoma or raised intraocular pressure: a review.

Open-angle glaucoma is characterized by **increased intraocular pressure** due to increased secretion or decreased outflow of aqueous humor. It is a form of optic neuropathy and causes progressive loss of ganglion cell axons, which may be visualized as a pale optic disc and enlarged optic cup (compared to normal retina). Symptoms evolve over decades, with progressive loss of **peripheral visual fields**.

Glaucoma is managed with agents that either decrease production or increase outflow of aqueous humor. Latanoprost is a topical **prostaglandin** used in the treatment of glaucoma. It is applied as a prodrug and converted to the active form by esterases in the cornea. Prostaglandins are the preferred first-line agents for the treatment of glaucoma, and although the exact mechanism of action is uncertain, they have been found to decrease the collagen content in the uveoscleral outflow pathway and **increase outflow** of aqueous humor. They are also known to cause increased pigmentation in the iris and eyelashes.

(Choices A, C, and E) Carbonic anhydrase inhibitors (eg, dorzolamide) decrease formation of bicarbonate in the ciliary body, leading to decreased sodium and fluid transport and subsequently decreased production of aqueous humor. Alpha-adrenergic agonists (eg, brimonidine) inhibit production of aqueous humor due to vasoconstriction in the ciliary body. Beta blockers (eg, timolol) also decrease production of aqueous humor. Prostaglandins do not affect production of aqueous humor but are often used in combination with these other agents.

(Choice B) Increased formation of new blood vessels at the optic disc is the characteristic feature of proliferative diabetic retinopathy. Strict control of diabetes will reduce the risk of diabetic retinopathy, but it is not affected by topical prostaglandins.

Educational objective:
Glaucoma is a form of optic neuropathy characterized by increased intraocular pressure associated with increased production or decreased outflow of aqueous humor. Topical prostaglandins (eg, latanoprost) increase outflow of aqueous via the uveoscleral pathway and are the preferred treatment for open-angle glaucoma.

References

- Latanoprost ophthalmic solution in the treatment of open angle glaucoma or raised intraocular pressure: a review.

Pharmacology	Ophthalmology	Glaucoma
Subject	System	Topic

Copyright © UWorld. All rights reserved.

Open-angle glaucoma is characterized by **increased intraocular pressure** due to increased secretion or decreased outflow of aqueous humor.

Exhibit Display

Glaucomatous optic atrophy (moderate)

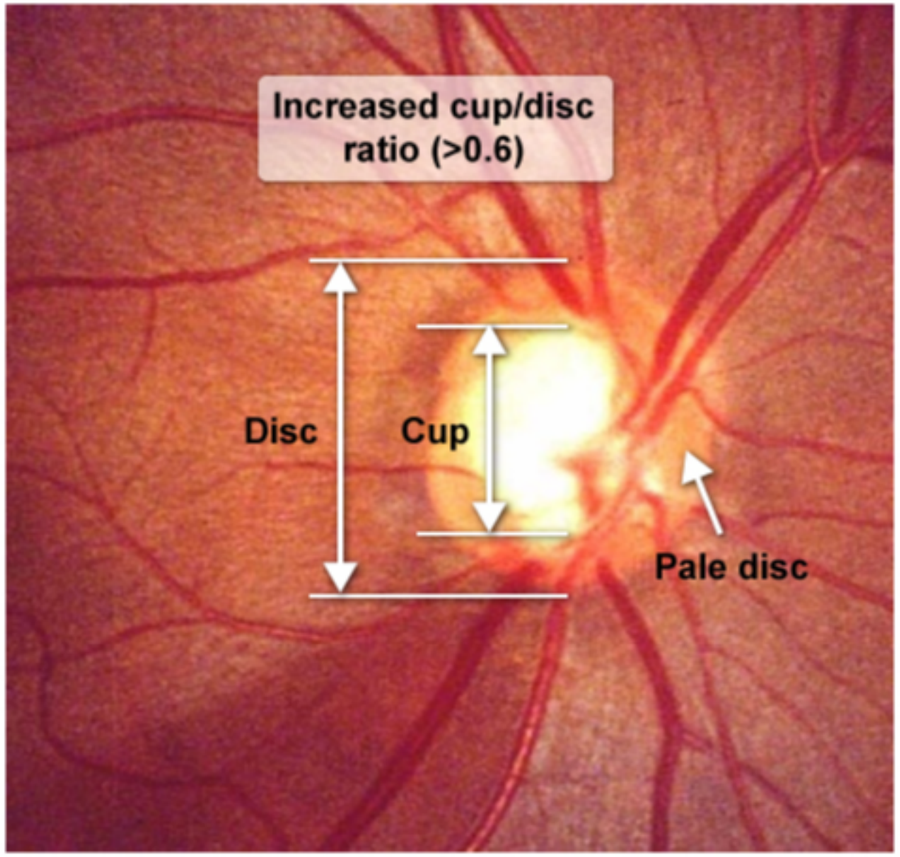

©UWorld

Zoom In | Zoom Out | Reset | Add To New Card | Existing Card

Open-angle glaucoma is characterized by **increased intraocular pressure** due to increased secretion or decreased outflow of aqueous humor.

Exhibit Display

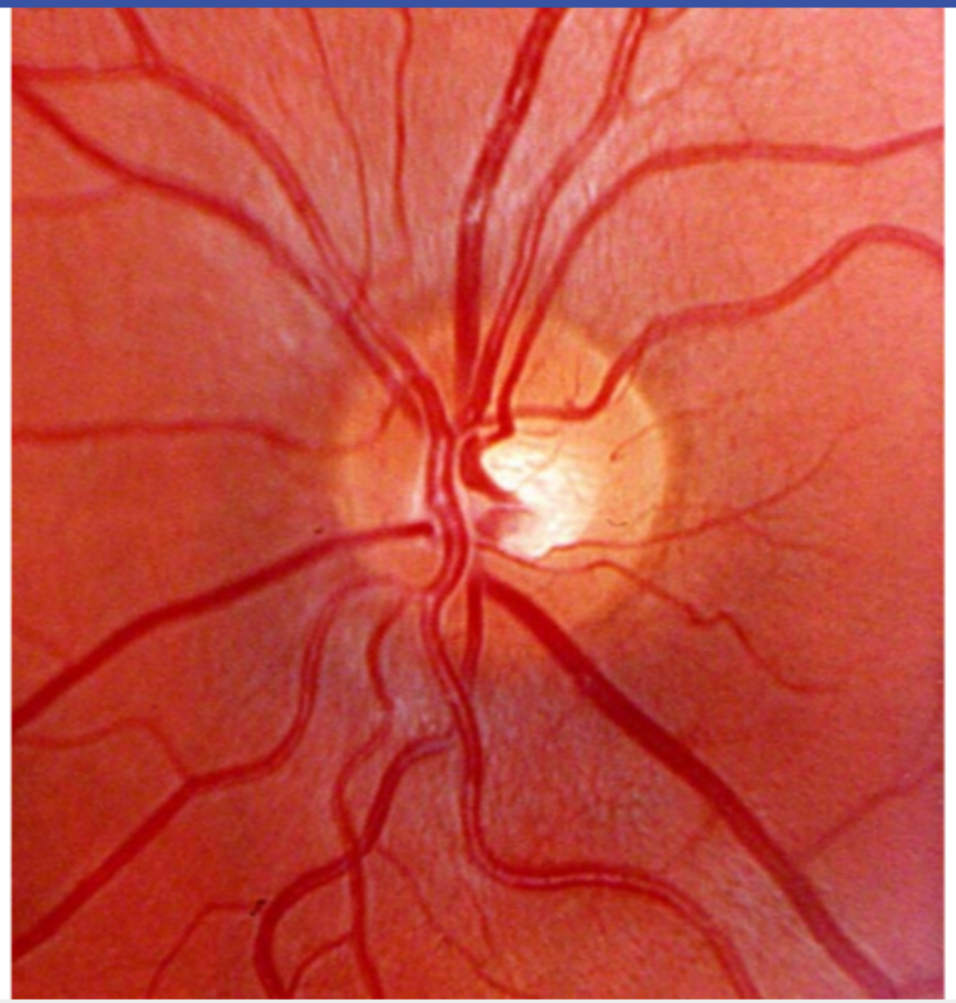

Zoom In | Zoom Out | Reset | Add To New Card | Existing Card

A 62-year-old woman comes to the emergency department due to acute eye pain. She has a history of seasonal allergies and developed itchy, watery, red eyes after working outdoors in her garden. The patient used over-the-counter eye drops to treat her allergy symptoms, and several hours later, she began experiencing severe right eye pain and headache. On examination, the right eye appears red with a hazy cornea and dilated pupil that responds poorly to light. Palpation of the globes reveals notable firmness on the right compared to the left. Visual acuity in the affected eye is severely diminished. Tonometry reveals elevated intraocular pressure. Which of the following medications was most likely used by this patient?

A. Alpha-adrenergic agonist

B. Beta blocker

C. Mast cell stabilizer

D. Nonsteroidal anti-inflammatory drug

E. Prostaglandin analogue

Submit

A 62-year-old woman comes to the emergency department due to acute eye pain. She has a history of seasonal allergies and developed itchy, watery, red eyes after working outdoors in her garden. The patient used over-the-counter eye drops to treat her allergy symptoms, and several hours later, she began experiencing severe right eye pain and headache. On examination, the right eye appears red with a hazy cornea and dilated pupil that responds poorly to light. Palpation of the globes reveals notable firmness on the right compared to the left. Visual acuity in the affected eye is severely diminished. Tonometry reveals elevated intraocular pressure. Which of the following medications was most likely used by this patient?

- ✓ A. Alpha-adrenergic agonist (70%)
- B. Beta blocker (8%)
- C. Mast cell stabilizer (5%)
- D. Nonsteroidal anti-inflammatory drug (6%)
- E. Prostaglandin analogue (9%)

Omitted
Correct answer
A

70%
Answered correctly

02 secs
Time Spent

02/16/2020
Last Updated

Explanation

Angle-closure glaucoma

Normal eye

Angle-closure glaucoma

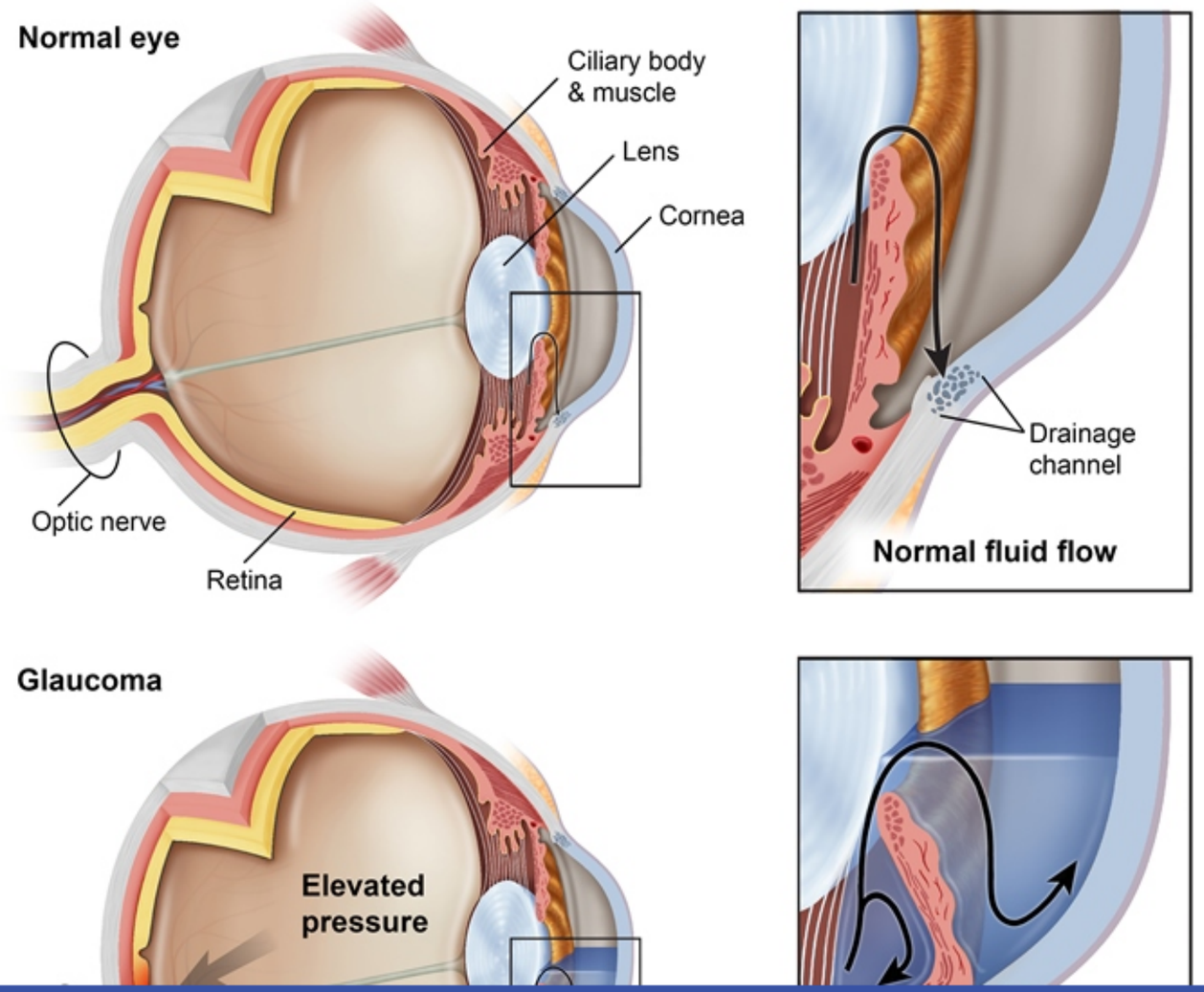

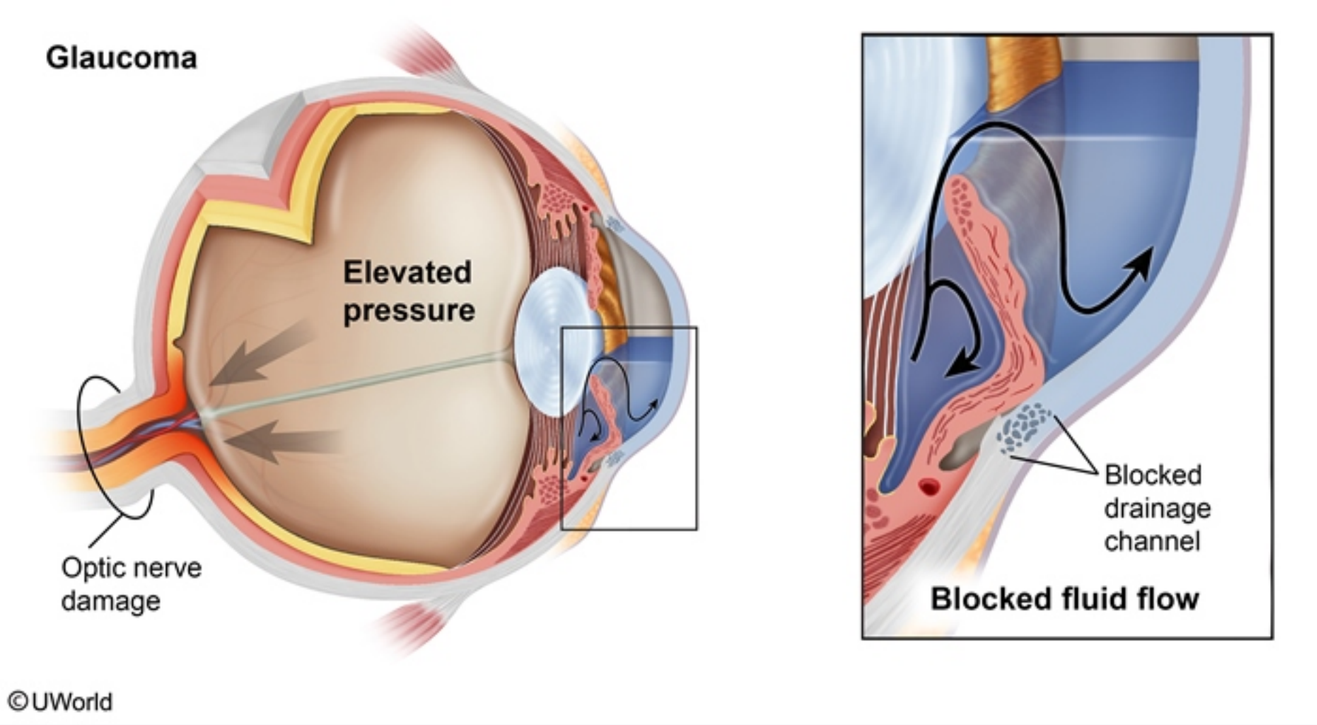

This patient is presenting with **angle-closure glaucoma** (ACG) that was precipitated by use of over-the-counter eye drops. ACG typically occurs in patients with a predisposing narrow chamber angle and develops when the normal drainage pathway of aqueous humor becomes blocked.

Aqueous humor is produced by the ciliary body and flows from the posterior chamber of the eye through the pupil into the anterior chamber and out of the eye via the trabecular network. In susceptible individuals, dilation of the pupil causes the iris to press against the anterior surface of the lens. This limits flow of aqueous humor through the pupil, causing the iris to bulge forward. The corresponding reduction (closing) of the iridocorneal angle blocks drainage of aqueous humor through the trabecular meshwork.

Acute ACG may be precipitated by topical and systemic medications that cause **pupillary dilation**, such as **alpha-adrenergic agonists** (eg, naphazoline) and drugs with strong **anticholinergic** effects (eg, tricyclic antidepressants, antihistamines). Acute blockage results in a rapid rise in intraocular pressure that typically causes **severe eye pain**, **conjunctival injection**, and **corneal edema** (haziness). If not corrected, the elevated pressure can damage the optic nerve and cause permanent vision impairment.

©UWorld

This patient is presenting with **angle-closure glaucoma** (ACG) that was precipitated by use of over-the-counter eye drops. ACG typically occurs in patients with a predisposing narrow chamber angle and develops when the normal drainage pathway of aqueous humor becomes blocked.

Aqueous humor is produced by the ciliary body and flows from the posterior chamber of the eye through the pupil into the anterior chamber and out of the eye via the trabecular network. In susceptible individuals, dilation of the pupil causes the iris to press against the anterior surface of the lens. This limits flow of aqueous humor through the pupil, causing the iris to bulge forward. The corresponding reduction (closing) of the iridocorneal angle blocks drainage of aqueous humor through the trabecular meshwork.

Acute ACG may be precipitated by topical and systemic medications that cause **pupillary dilation**, such as **alpha-adrenergic agonists** (eg, naphazoline) and drugs with strong **anticholinergic** effects (eg, tricyclic antidepressants, antihistamines). Acute blockage results in a rapid rise in intraocular pressure that typically causes **severe eye pain**, **conjunctival injection**, and **corneal edema** (haziness). If not corrected, the elevated pressure can damage the optic nerve and cause permanent vision impairment.

(Choice B) Topical beta blockers (eg, timolol) are used to treat open-angle glaucoma. They work by both reducing the production of aqueous humor and increasing its outflow from the trabecular network.

(Choices C and D) Topical mast cell stabilizers (eg, cromolyn, nedocromil) and nonsteroidal anti-inflammatory drugs (eg, ketorolac) are used in the treatment of allergic conjunctivitis, but they are not associated with ACG.

(Choice E) Prostaglandin analogues such as latanoprost increase aqueous outflow from the trabecular network and are used in the treatment of open-angle glaucoma.

Educational objective:
Acute angle-closure glaucoma occurs when the space between the cornea and iris is narrowed, limiting the flow of aqueous humor out of the anterior chamber and raising pressure in the eye. Medications that cause pupillary dilation (eg, alpha-adrenergic agonists, anticholinergics) can trigger acute angle-closure glaucoma.

References

- The pathophysiology and treatment of glaucoma: a review.

A male neonate is born prematurely to 22-year-old primigravida and experiences severe respiratory distress. The distress resolves with treatment, and by two weeks of age, the patient has adequate respiratory function. Ophthalmoscopy later shows abnormal retinal vascularization that extends into the vitreous. The retinal findings in this patient are most likely related to:

A. Maternal terbutaline treatment

B. Maternal corticosteroid therapy

C. Neonatal antibiotic treatment

D. Neonatal oxygen supplementation

E. Neonatal surfactant supplementation

Submit

A male neonate is born prematurely to 22-year-old primigravida and experiences severe respiratory distress. The distress resolves with treatment, and by two weeks of age, the patient has adequate respiratory function. Ophthalmoscopy later shows abnormal retinal vascularization that extends into the vitreous. The retinal findings in this patient are most likely related to:

A. Maternal terbutaline treatment (2%)
B. Maternal corticosteroid therapy (9%)
C. Neonatal antibiotic treatment (2%)
✓ D. Neonatal oxygen supplementation (76%)
E. Neonatal surfactant supplementation (8%)

Omitted
Correct answer
D

76%
Answered correctly

02 secs
Time Spent

02/03/2020
Last Updated

Explanation

Respiratory distress in a premature neonate is most commonly due to pulmonary surfactant deficiency resulting in hyaline membrane disease. Treatment involves administration of supplemental oxygen at high concentrations, nasal continuous positive airway pressure, and/or mechanical ventilation with intratracheal surfactant. One potential adverse effect of oxygen therapy is retinal damage.

Temporary local hyperoxia in the retina is thought to induce changes that cause up-regulation of proangiogenic factors such as vascular endothelial growth factor (VEGF) upon return to room air ventilation. Retinal vessel proliferation *(neovascularization)* and possible retinal detachment with blindness may result. This complication of neonatal respiratory distress syndrome is referred to as retinopathy of prematurity or

Explanation

Respiratory distress in a premature neonate is most commonly due to pulmonary surfactant deficiency resulting in hyaline membrane disease. Treatment involves administration of supplemental oxygen at high concentrations, nasal continuous positive airway pressure, and/or mechanical ventilation with intratracheal surfactant. One potential adverse effect of oxygen therapy is retinal damage.

Temporary local hyperoxia in the retina is thought to induce changes that cause up-regulation of proangiogenic factors such as vascular endothelial growth factor (VEGF) upon return to room air ventilation. Retinal vessel proliferation *(neovascularization)* and possible retinal detachment with blindness may result. This complication of neonatal respiratory distress syndrome is referred to as retinopathy of prematurity or retrolental fibroplasia.

(Choice A) Terbutaline is a β-mimetic tocolytic drug used to delay labor and delivery by suppressing uterine contractions. Use of terbutaline has been linked to an increased risk of neonatal intraventricular hemorrhage, hypoglycemia, hypocalcemia, and ileus.

(Choice B) Corticosteroids may be administered to pregnant women entering premature labor in an effort to induce surfactant production by the fetal lungs. Maternal steroid treatment in the prenatal period does not cause neonatal retinal neovascularization.

(Choice C) Neonatal antibiotic treatment does not cause retinal neovascularization.

(Choice E) Complications of surfactant treatment may include transient hypoxia and hypotension, blockage of an endotracheal tube, and pulmonary hemorrhage. Retinal neovascularization is not a known complication.

Educational Objective:
Use of concentrated oxygen therapy for neonatal respiratory distress syndrome may be complicated by retinopathy of prematurity. This abnormal retinal neovascularization is a major cause of blindness in developed nations.

Pathology	Ophthalmology	Neonatal respiratory distress syndrome
Subject	System	Topic

Copyright © UWorld. All rights reserved.

A 22-year-old woman comes to the office for a routine prenatal visit. She is 16 weeks pregnant with her first child. Two months ago, she had a mononucleosis-like illness with fever, myalgia, and fatigue, and she was diagnosed with cytomegalovirus infection. The patient recovered with symptomatic treatment and is currently asymptomatic. Her other medical problems include episodic migraine headaches and benign choroidal nevus. She takes prenatal vitamins and does not use tobacco, alcohol, or illicit drugs. The patient has a family history of hypertension and glaucoma. Physical examination findings and prenatal ultrasound are unremarkable. This patient's unborn infant is at greatest risk for which of the following eye conditions?

- A. Chorioretinitis
- B. Choroidal nevus
- C. Congenital cataract
- D. Glaucoma
- E. Inclusion conjunctivitis
- F. Retinitis pigmentosa
- G. Retinoblastoma

Submit

A 22-year-old woman comes to the office for a routine prenatal visit. She is 16 weeks pregnant with her first child. Two months ago, she had a mononucleosis-like illness with fever, myalgia, and fatigue, and she was diagnosed with cytomegalovirus infection. The patient recovered with symptomatic treatment and is currently asymptomatic. Her other medical problems include episodic migraine headaches and benign choroidal nevus. She takes prenatal vitamins and does not use tobacco, alcohol, or illicit drugs. The patient has a family history of hypertension and glaucoma. Physical examination findings and prenatal ultrasound are unremarkable. This patient's unborn infant is at greatest risk for which of the following eye conditions?

- A. Chorioretinitis
- B. Choroidal nevus
- C. Congenital cataract
- D. Glaucoma
- E. Inclusion conjunctivitis
- F. Retinitis pigmentosa
- G. Retinoblastoma

Submit

A 22-year-old woman comes to the office for a routine prenatal visit. She is 16 weeks pregnant with her first child. Two months ago, she had a mononucleosis-like illness with fever, myalgia, and fatigue, and she was diagnosed with cytomegalovirus infection. The patient recovered with symptomatic treatment and is currently asymptomatic. Her other medical problems include episodic migraine headaches and benign choroidal nevus. She takes prenatal vitamins and does not use tobacco, alcohol, or illicit drugs. The patient has a family history of hypertension and glaucoma. Physical examination findings and prenatal ultrasound are unremarkable. This patient's unborn infant is at greatest risk for which of the following eye conditions?

- ✓ A. Chorioretinitis (60%)
- B. Choroidal nevus (2%)
- C. Congenital cataract (18%)
- D. Glaucoma (3%)
- E. Inclusion conjunctivitis (8%)
- F. Retinitis pigmentosa (5%)
- G. Retinoblastoma (1%)

Omitted
Correct answer
A

60%
Answered correctly

03 secs
Time Spent

01/18/2020
Last Updated

Explanation

Up to 5% of women develop a **primary cytomegalovirus (CMV) infection** (typically a mononucleosis-like illness with fever and mild hepatitis)

Up to 5% of women develop a **primary cytomegalovirus (CMV) infection** (typically a mononucleosis-like illness with fever and mild hepatitis) during pregnancy. Vertical transmission to the fetus occurs in approximately one-third of cases, with the highest risk of transmission occurring in the first trimester. **CMV-related complications** observed in infants exposed to the virus **in utero** include **chorioretinitis** (most common eye-related problem), sensorineural deafness, seizures, jaundice, hepatomegaly, splenomegaly, and microcephaly.

(Choice B) Choroidal nevus (eye freckle) is a nonhereditary, usually benign pigmented area underneath the retina and is not associated with in-utero CMV infection.

(Choice C) Congenital cataract can be seen with in-utero rubella infection.

(Choice D) Glaucoma can be present at birth and may be primary or secondary (eg, tumor). However, it is not a known complication of CMV infection.

(Choice E) Inclusion conjunctivitis is seen with *Chlamydia trachomatis* infection of the newborn.

(Choice F) Retinitis pigmentosa is an inherited degenerative eye disease that leads to severe vision impairment and is not a complication of in-utero CMV infection.

(Choice G) Retinoblastoma is the most common malignant eye cancer in children and is caused by a chromosomal mutation that is hereditary or sporadic. CMV infection in utero is not associated with causing retinoblastoma.

Educational objective:
The most common eye-related complication of congenital cytomegalovirus infection is chorioretinitis.

References

- Ocular abnormalities in congenital cytomegalovirus infection.

Microbiology	Ophthalmology	Cytomegalovirus
Subject	System	Topic

Copyright © UWorld. All rights reserved.

A 75-year-old man comes to the office due to a 2-year history of slowly worsening vision in both eyes. The symptoms are worse at night and the patient has stopped driving at night due to excessive glare from oncoming headlights. He has worked his entire life as a farmer and continues to drive tractors and other farm equipment during the day without difficulty. Medical history is unremarkable. Ocular examination shows loss of the red reflex and poor visualization of retinal detail. Acuity testing shows 20/100 vision in both eyes; visual field testing is normal. Which of the following is the most likely etiologic factor for this patient's eye condition?

A. Accumulation of sorbitol in the lens

B. Age-related oxidative injury

C. Decreased collagen fibril production

D. Ischemia and neovascularization

E. Loss of lens distensibility

Submit

A 75-year-old man comes to the office due to a 2-year history of slowly worsening vision in both eyes. The symptoms are worse at night and the patient has stopped driving at night due to excessive glare from oncoming headlights. He has worked his entire life as a farmer and continues to drive tractors and other farm equipment during the day without difficulty. Medical history is unremarkable. Ocular examination shows loss of the red reflex and poor visualization of retinal detail. Acuity testing shows 20/100 vision in both eyes; visual field testing is normal. Which of the following is the most likely etiologic factor for this patient's eye condition?

A. Accumulation of sorbitol in the lens (21%)
✓ B. Age-related oxidative injury (55%)
C. Decreased collagen fibril production (3%)
D. Ischemia and neovascularization (4%)
E. Loss of lens distensibility (14%)

Omitted
Correct answer
B

55%
Answered correctly

02 secs
Time Spent

05/07/2020
Last Updated

Explanation

Clinical features of age-related cataract	
Risk factors	• Age >60 • Chronic sunlight exposure • Diabetes mellitus

Clinical features of age-related cataract	
Risk factors	• Age >60 • Chronic sunlight exposure • Diabetes mellitus • Glucocorticoid use • Smoking • HIV infection
Symptoms	• Gradual loss of visual acuity • Excessive glare, halos around bright lights • Myopic shift
Signs	• Opacification of lens • Loss of red reflex

This patient has **cataracts**: progressive opacification of the lenses with chronic **loss of visual acuity**. Scattering of light within the lens leads to glare and halos around bright lights, especially at night. Examination reveals cloudiness in the lens, decreased detail when examining the retina, and loss of the red reflex.

Transparency of the lens requires an ordered epithelial cell structure and maintenance of intracellular crystallins. **Aging** and environmental stressors can disrupt transparency and contribute to cataract formation through the following mechanisms:

- **Nuclear sclerosis**: new layers of epithelia form on the cortex of the lens, compacting older layers beneath
- **Photooxidative damage** and cross-linking of crystallins causes brown/yellow pigmentary changes
- **Osmotic injury** resulting in development of hydropic lens fibers that degenerate

Cumulative photooxidative stress is worsened by heavy **UV exposure** (eg, outdoor occupations), smoking, or ionizing radiation. Likewise, osmotic injury is accelerated in patients with diabetes mellitus. A disordered balance of prooxidative versus antioxidative compounds in the lens (eg, decreased glutathione) may also contribute.

Signs	• Opacification of lens • Loss of red reflex

This patient has **cataracts**: progressive opacification of the lenses with chronic **loss of visual acuity**. Scattering of light within the lens leads to glare and halos around bright lights, especially at night. Examination reveals cloudiness in the lens, decreased detail when examining the retina, and loss of the red reflex.

Transparency of the lens requires an ordered epithelial cell structure and maintenance of intracellular crystallins. **Aging** and environmental stressors can disrupt transparency and contribute to cataract formation through the following mechanisms:

- **Nuclear sclerosis**: new layers of epithelia form on the cortex of the lens, compacting older layers beneath
- **Photooxidative damage** and cross-linking of crystallins causes brown/yellow pigmentary changes
- **Osmotic injury** resulting in development of hydropic lens fibers that degenerate

Cumulative photooxidative stress is worsened by heavy **UV exposure** (eg, outdoor occupations), smoking, or ionizing radiation. Likewise, osmotic injury is accelerated in patients with diabetes mellitus. A disordered balance of prooxidative versus antioxidative compounds in the lens (eg, decreased glutathione) may also contribute.

(Choice A) In patients with diabetes, excess glucose is converted to sorbitol at a greater rate than sorbitol can be metabolized to fructose. Osmotic injury due to the higher concentration of sorbitol in the lens can lead to cataract. However, in patients without diabetes, the conversion of sorbitol to fructose is adequate to prevent the buildup of sorbitol.

(Choice C) Photoaging of skin is characterized by decreased collagen fibril production and loss of tissue elasticity in sun-exposed areas. However, defects in collagen production are not a significant contributor to cataract.

(Choice D) Microvascular ischemia in patients with long-standing diabetes can cause neovascularization in the retina, leading to diabetic retinopathy. Most patients are asymptomatic until late in the course of the disease, when vitreous hemorrhage or retinal detachment causes acute vision loss.

(Choice E) Presbyopia is a type of refractive error caused by loss of the normal distensibility of the lens with age. It reduces the ability of the eye to focus on near objects but does not cause loss of visual acuity.

1
2
3
4
5
6
7
8
9
10
11
12
13
14
15
16
17
18
19
20
21

Signs

- Opacification of lens

Exhibit Display

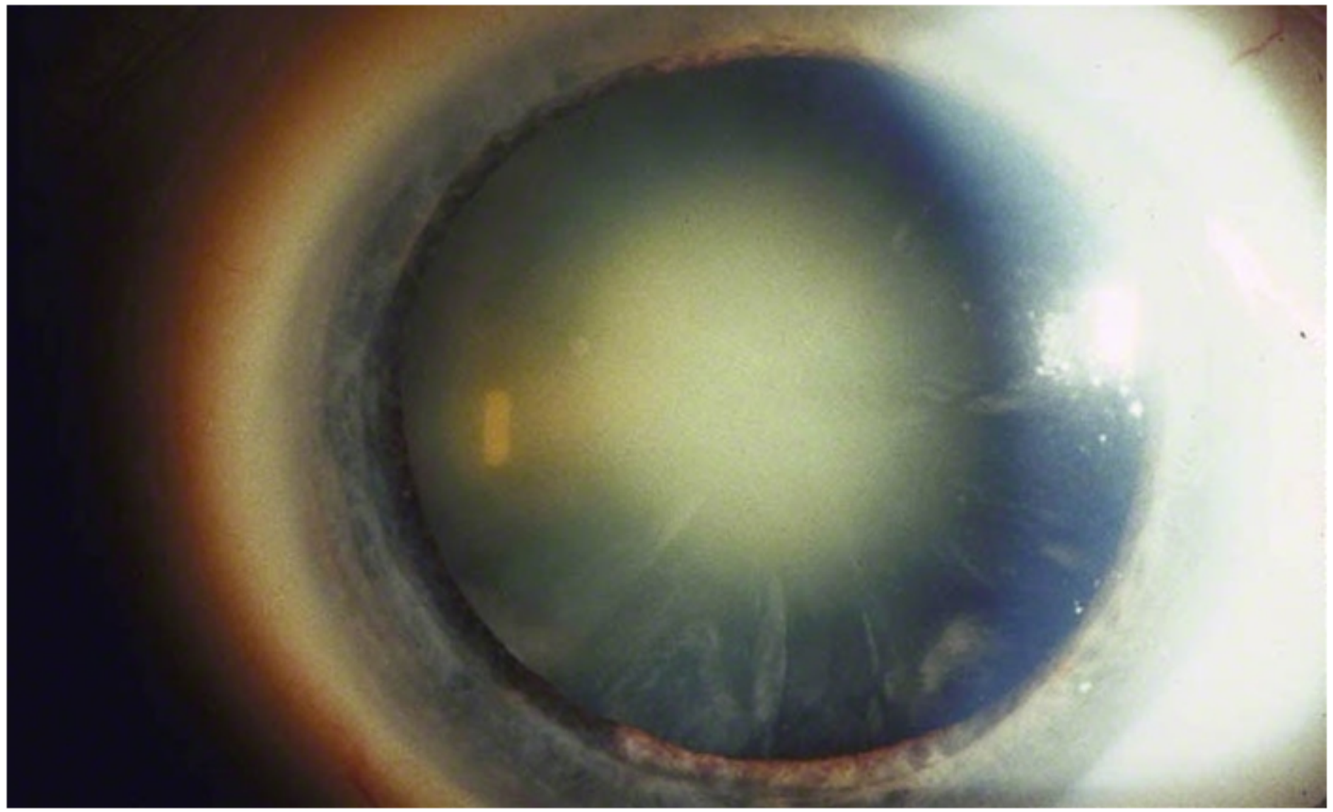

Zoom In
Zoom Out
Reset
Add To Flash Card

Signs
- Opacification of lens

Exhibit Display

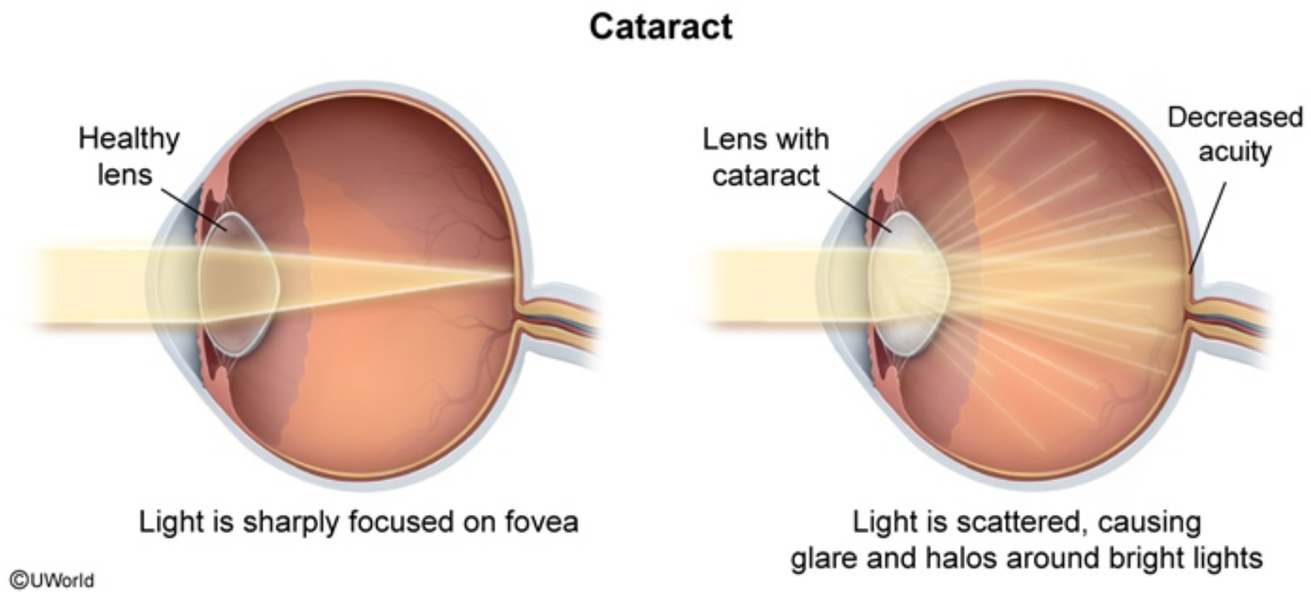

Zoom In
Zoom Out
Reset
Add To Flash Card

Signs
- Opacification of lens

Exhibit Display

Normal eyes & white reflex

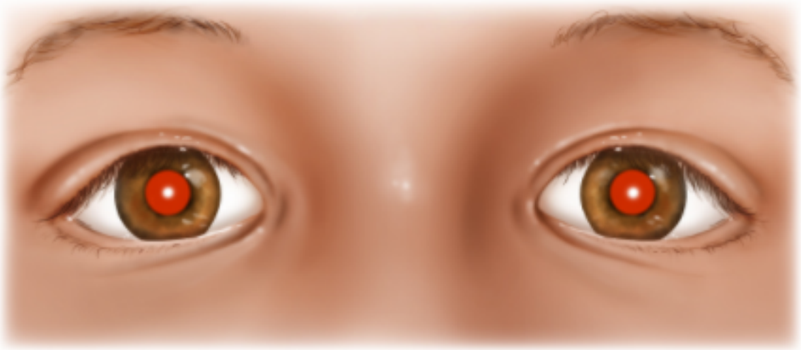

Normal eyes
Red reflexes & corneal light reflexes are equal.

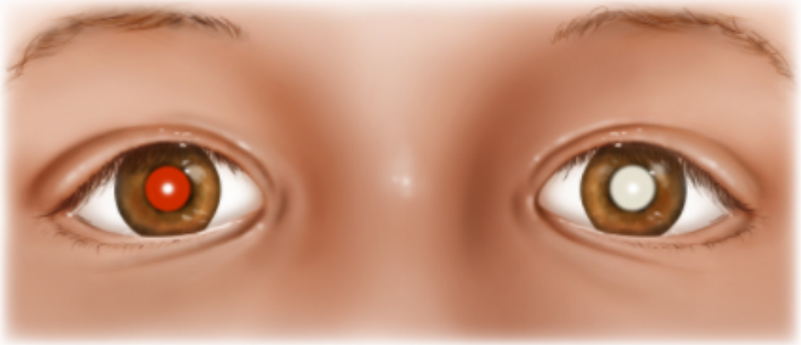

Absent reflex
White reflex on abnormal eye can result from opacities of the lens (eg, cataract) or tumor (eg, retinoblastoma).

©UWorld

Zoom In
Zoom Out
Reset
Add To Flash Card

1
2
3
4
5
6
7
8
9
10
11
12
13
14
15
16
17
18
19
20
21

Signs
- Opacification of lens

Exhibit Display

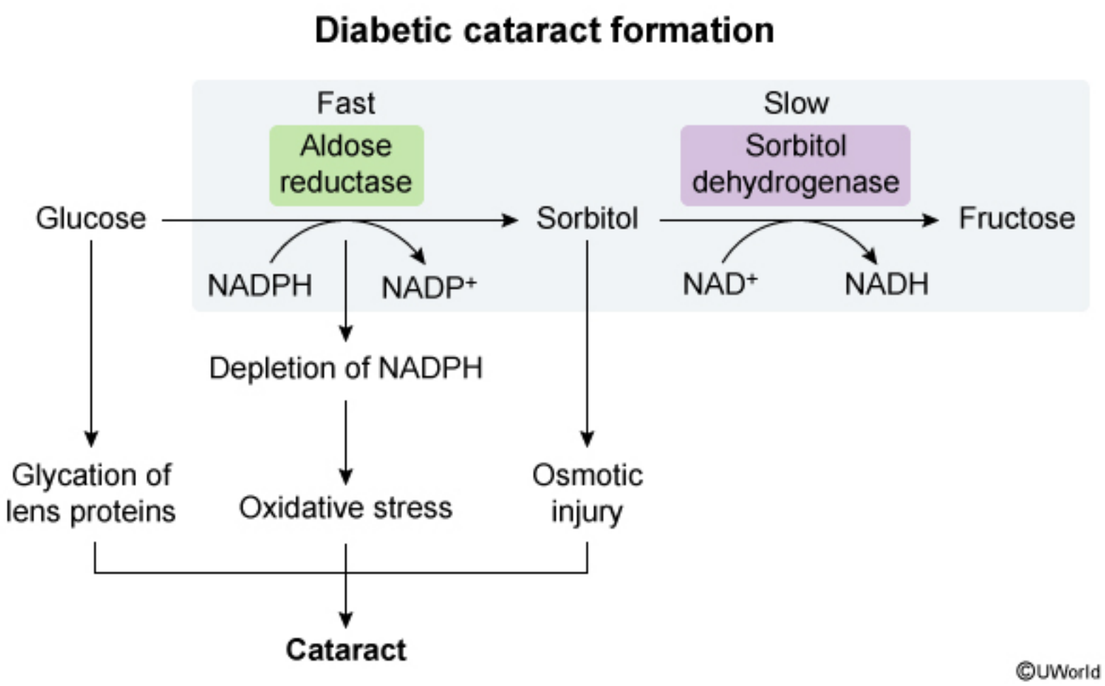

Zoom In
Zoom Out
Reset
Add To Flash Card

A 31-year-old woman comes to the office due to transient visual changes that are characterized by "loss of vision for a minute" and commonly precipitated by bending forward or lifting objects. During the last 3 months, she has had persistent headaches that she attributes to migraines. The patient takes over-the-counter analgesics as needed. Blood pressure is 140/90 mm Hg and pulse is 72/min and regular. BMI is 32.4 kg/m^2. Funduscopic findings of the left eye are shown in the image below, with similar findings in the right eye.

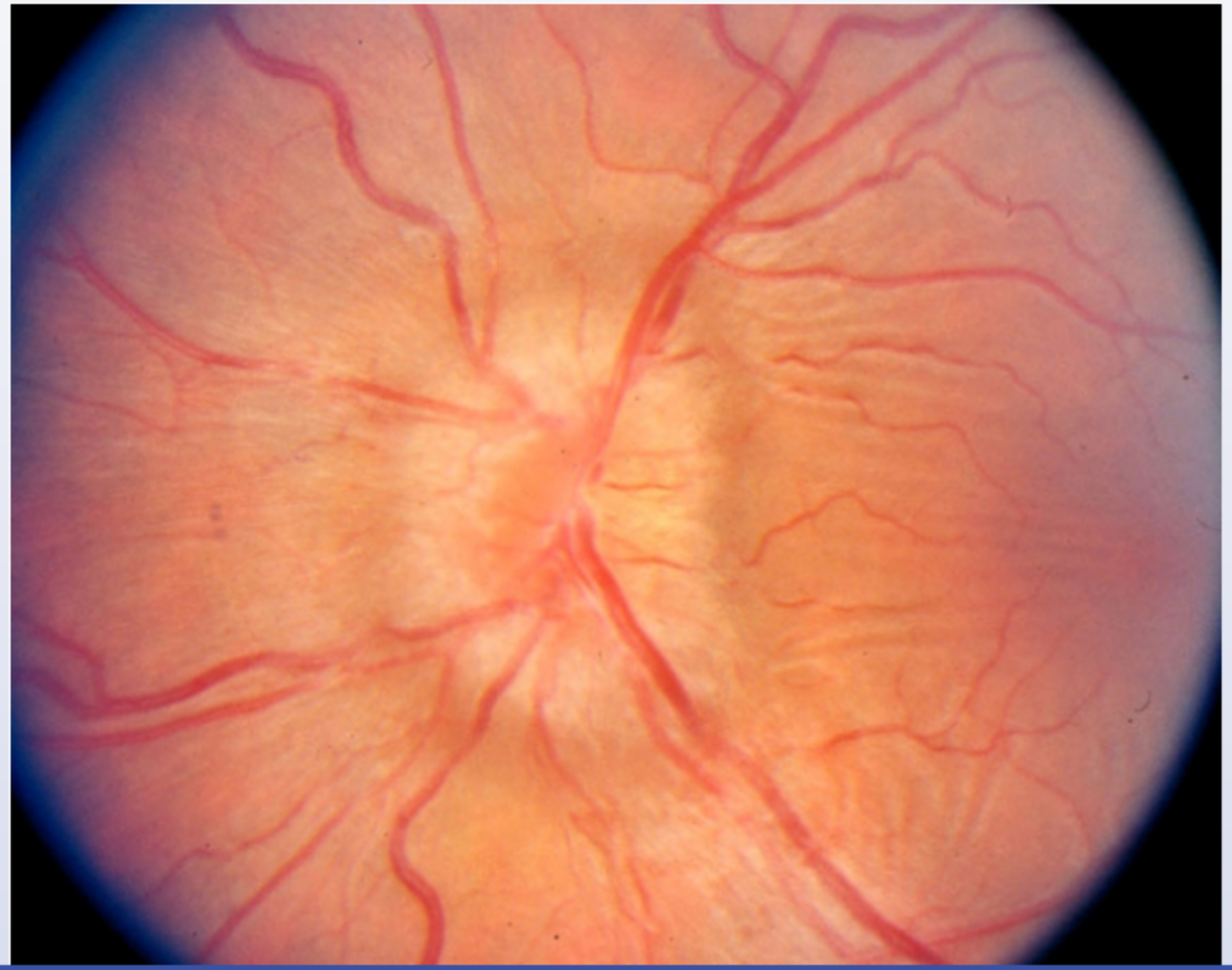

1
2
3
4
5
6
7
8
9
10
11
12
13
14
15
16
17
18
19
20
21

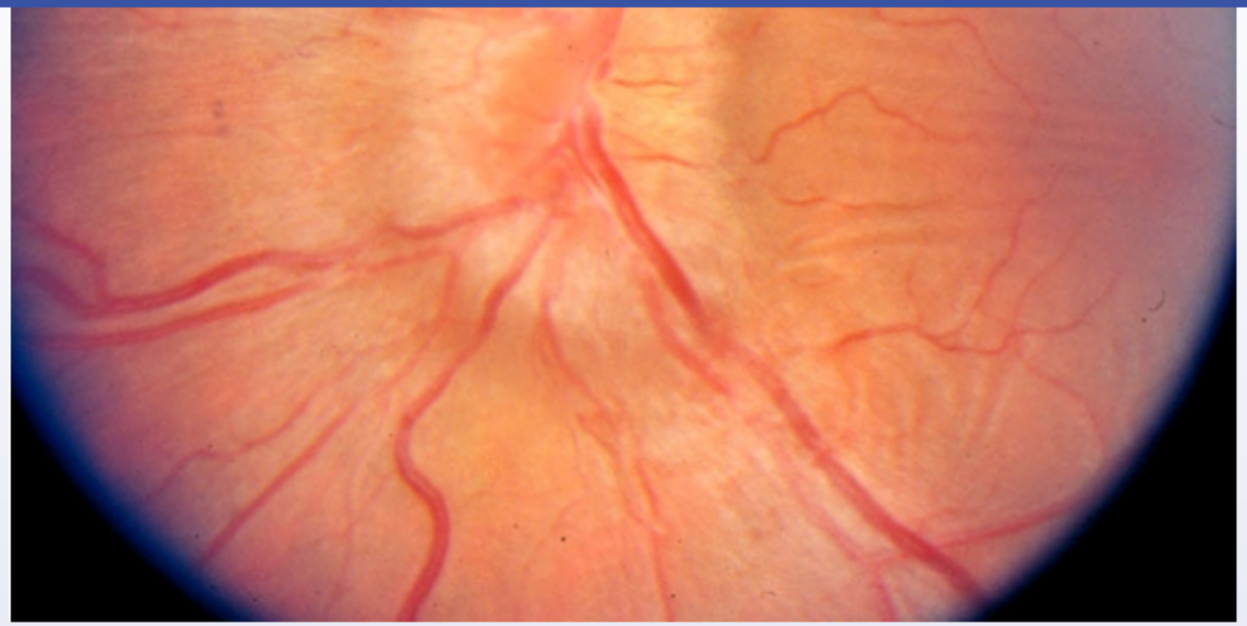

Which of the following is the most likely cause of the observed funduscopic findings in this patient?

A. Choroidal inflammation

B. Elevated intracranial pressure

C. Elevated intraocular pressure

D. Optic nerve inflammation

E. Retinal ischemia

Submit

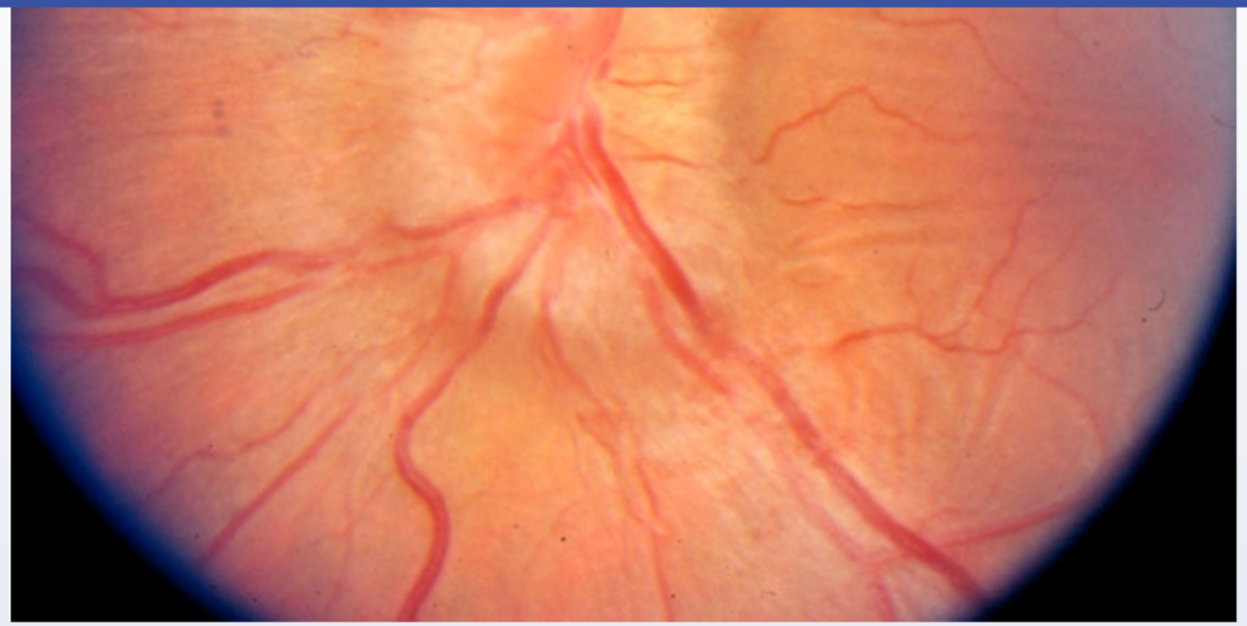

Which of the following is the most likely cause of the observed funduscopic findings in this patient?

- A. Choroidal inflammation (0%)
- ✓ B. Elevated intracranial pressure (70%)
- C. Elevated intraocular pressure (17%)
- D. Optic nerve inflammation (3%)
- E. Retinal ischemia (8%)

Omitted
Correct answer

70%
Answered correctly

06 secs
Time Spent

07/01/2020
Last Updated

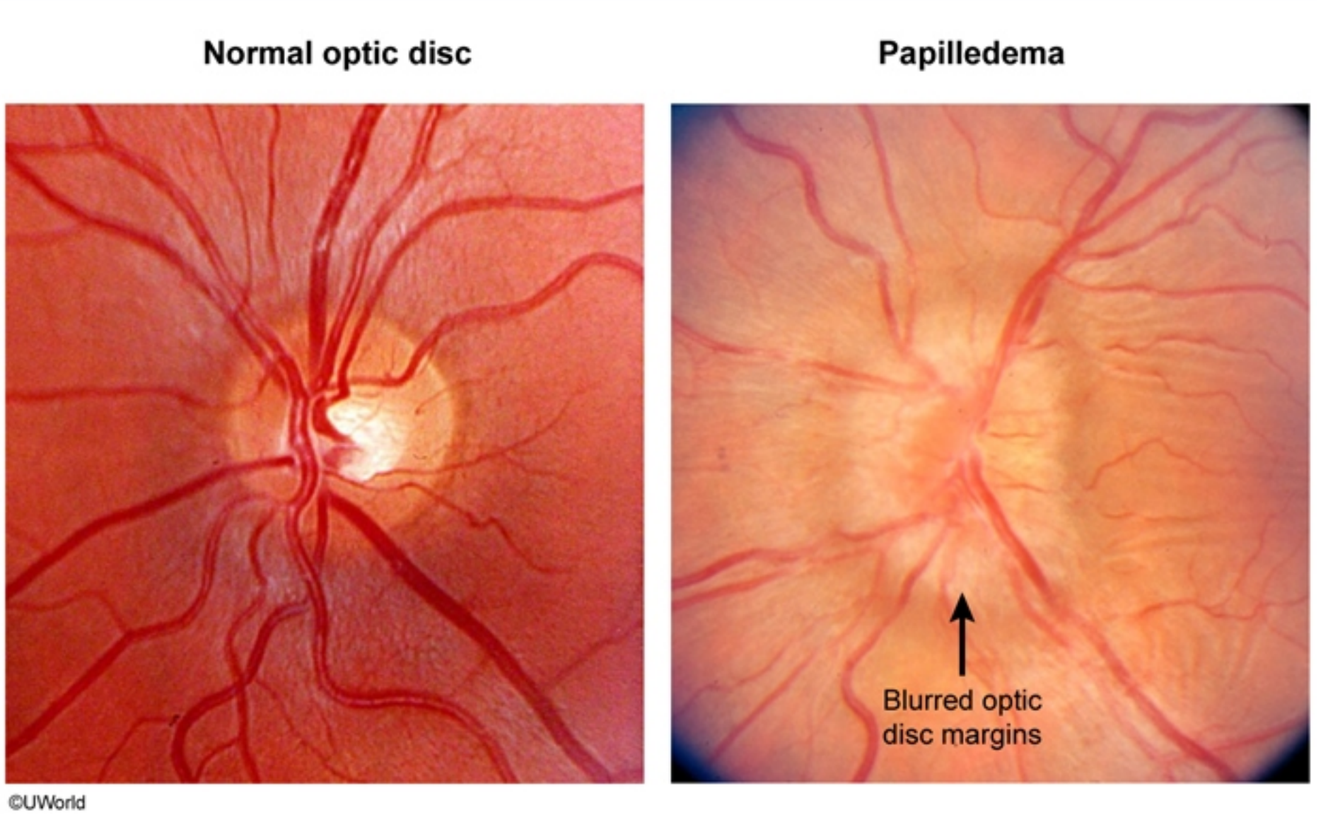

This patient's clinical presentation is consistent with **idiopathic intracranial hypertension** (pseudotumor cerebri). This condition typically presents in young obese women with **daily headache**, bilaterally symmetric papilledema, and **transient visual disturbances** related to impaired cerebral venous outflow and **elevated intracranial pressure**. Symptoms characteristically worsen during the Valsalva maneuver (eg, bending down, coughing) because intracranial pressure increases.

Increased intracranial pressure is transmitted through the cerebrospinal fluid in the subarachnoid space, which is continuous with the optic nerve sheath. This buildup of pressure compresses the optic nerves externally, which in turn **impairs axoplasmic flow** within the **optic nerves**, causing bilateral optic disc edema **(papilledema)**. Funduscopy shows elevation of the optic disc with blurred disc margins.

©UWorld

This patient's clinical presentation is consistent with **idiopathic intracranial hypertension** (pseudotumor cerebri). This condition typically presents in young obese women with **daily headache**, bilaterally symmetric papilledema, and **transient visual disturbances** related to impaired cerebral venous outflow and **elevated intracranial pressure**. Symptoms characteristically worsen during the Valsalva maneuver (eg, bending down, coughing) because intracranial pressure increases.

Increased intracranial pressure is transmitted through the cerebrospinal fluid in the subarachnoid space, which is continuous with the optic nerve sheath. This buildup of pressure compresses the optic nerves externally, which in turn **impairs axoplasmic flow** within the **optic nerves**, causing bilateral optic disc edema **(papilledema)**. Funduscopy shows elevation of the optic disc with blurred disc margins.

(Choice A) Choroidal inflammation is characteristic of posterior uveitis, which typically presents with painless vision loss and floaters. Ophthalmic examination may show inflammation/leukocytes in the vitreous humor. Uveitis is often associated with systemic inflammatory disorders (eg, inflammatory bowel disease, ankylosing spondylitis).

(Choice C) An acute increase in intraocular pressure is characteristic of angle-closure glaucoma, which typically presents with painful monocular vision loss, headache, vomiting, and conjunctival injection with a poorly reactive middilated pupil. Chronic increases in intraocular pressure can cause optic disc cupping due to atrophy of the optic nerve head. Glaucoma usually affects older individuals.

(Choice D) Optic neuritis is frequently associated with multiple sclerosis, a demyelinating CNS disease that typically affects women age 15-50. Although swelling of the optic disc can be present on funduscopy, optic neuritis usually causes sustained monocular vision loss over several weeks with painful eye movement rather than daily headaches with transient bilateral vision loss.

(Choice E) Retinal ischemia can manifest with painless transient monocular vision loss (amaurosis fugax) and is most commonly caused by atherosclerotic emboli originating from the ipsilateral carotid artery. Funduscopy may show embolic plaques and retinal whitening caused by ischemia. This condition typically affects older patients with vascular risk factors (eg, hypertension, hyperlipidemia, diabetes mellitus).

Educational objective:
Idiopathic intracranial hypertension (pseudotumor cerebri) presents in young obese women with daily headache (which worsens during the Valsalva maneuver), bilaterally symmetric papilledema, and transient visual disturbances. Increased intracranial pressure compresses the optic nerves, resulting in impaired axoplasmic flow and optic disc edema.

References

cerebral venous outflow and **elevated intracranial pressure**. Symptoms characteristically worsen during the Valsalva maneuver (eg, bending down, coughing) because intracranial pressure increases.

Increased intracranial pressure is transmitted through the cerebrospinal fluid in the subarachnoid space, which is continuous with the optic nerve sheath. This buildup of pressure compresses the optic nerves externally, which in turn **impairs axoplasmic flow** within the **optic nerves**, causing bilateral optic disc edema **(papilledema)**. Funduscopy shows elevation of the optic disc with blurred disc margins.

(Choice A) Choroidal inflammation is characteristic of posterior uveitis, which typically presents with painless vision loss and floaters. Ophthalmic examination may show inflammation/leukocytes in the vitreous humor. Uveitis is often associated with systemic inflammatory disorders (eg, inflammatory bowel disease, ankylosing spondylitis).

(Choice C) An acute increase in intraocular pressure is characteristic of angle-closure glaucoma, which typically presents with painful monocular vision loss, headache, vomiting, and conjunctival injection with a poorly reactive middilated pupil. Chronic increases in intraocular pressure can cause optic disc cupping due to atrophy of the optic nerve head. Glaucoma usually affects older individuals.

(Choice D) Optic neuritis is frequently associated with multiple sclerosis, a demyelinating CNS disease that typically affects women age 15-50. Although swelling of the optic disc can be present on funduscopy, optic neuritis usually causes sustained monocular vision loss over several weeks with painful eye movement rather than daily headaches with transient bilateral vision loss.

(Choice E) Retinal ischemia can manifest with painless transient monocular vision loss (amaurosis fugax) and is most commonly caused by atherosclerotic emboli originating from the ipsilateral carotid artery. Funduscopy may show embolic plaques and retinal whitening caused by ischemia. This condition typically affects older patients with vascular risk factors (eg, hypertension, hyperlipidemia, diabetes mellitus).

Educational objective:
Idiopathic intracranial hypertension (pseudotumor cerebri) presents in young obese women with daily headache (which worsens during the Valsalva maneuver), bilaterally symmetric papilledema, and transient visual disturbances. Increased intracranial pressure compresses the optic nerves, resulting in impaired axoplasmic flow and optic disc edema.

References

- Pathogenesis of optic disc edema in raised intracranial pressure.
- Pseudotumor cerebri: brief review of clinical syndrome and imaging findings.

cerebral venous outflow and **elevated intracranial pressure**. Symptoms characteristically worsen during the Valsalva maneuver (eg, bending

Exhibit Display

Glaucomatous optic atrophy (advanced)

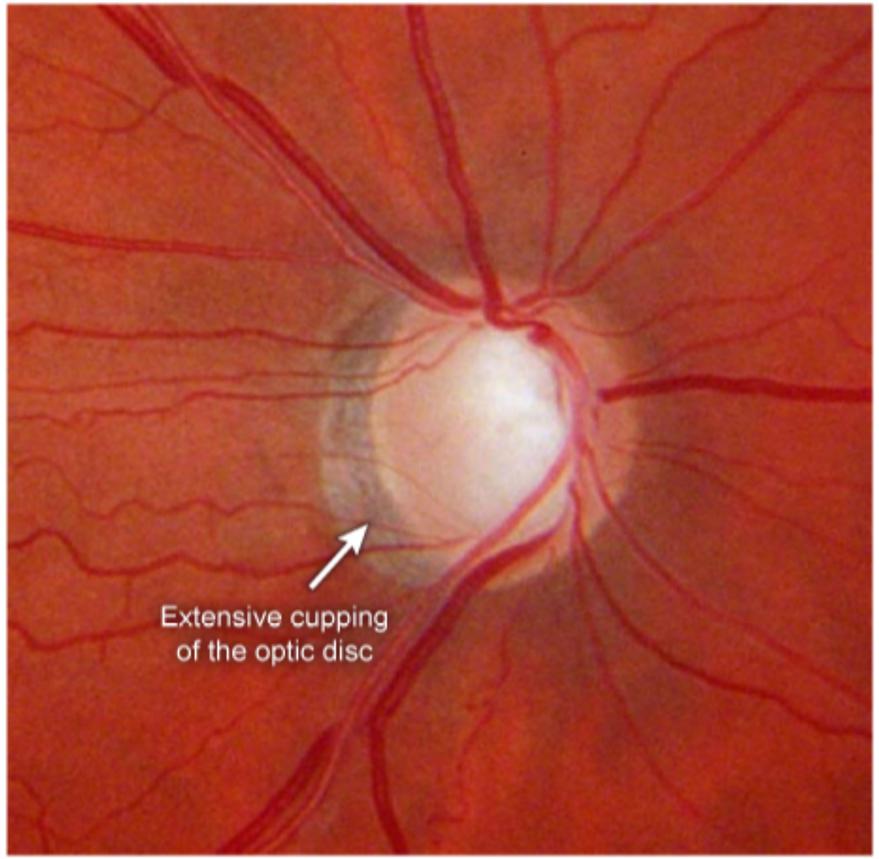

©UWorld

Zoom In | Zoom Out | Reset | Add To New Card | Existing Card

A 45-year-old woman comes to the office due to progressive visual difficulty with night driving and reading road signs and fine print. The patient has systemic lupus erythematosus, which is treated with hydroxychloroquine and prednisone. She avoids sun exposure due to photosensitivity and has vitamin D deficiency for which she takes a vitamin D supplement. Examination shows opacities on the posterior side of the lenses in both eyes. Optic discs are normal. Ocular movements are full. The remainder of the examination shows no abnormalities. Which of the following is the most significant contributing factor for the eye findings in this patient?

A. Hydroxychloroquine

B. Lack of sun exposure

C. Prednisone

D. Systemic lupus erythematous

E. Vitamin D deficiency

Submit

A 45-year-old woman comes to the office due to progressive visual difficulty with night driving and reading road signs and fine print. The patient has systemic lupus erythematosus, which is treated with hydroxychloroquine and prednisone. She avoids sun exposure due to photosensitivity and has vitamin D deficiency for which she takes a vitamin D supplement. Examination shows opacities on the posterior side of the lenses in both eyes. Optic discs are normal. Ocular movements are full. The remainder of the examination shows no abnormalities. Which of the following is the most significant contributing factor for the eye findings in this patient?

A. Hydroxychloroquine (35%)
B. Lack of sun exposure (2%)
✓ C. Prednisone (47%)
D. Systemic lupus erythematous (12%)
E. Vitamin D deficiency (1%)

Omitted
Correct answer
C

47%
Answered correctly

02 secs
Time Spent

04/02/2020
Last Updated

Explanation

Cataracts	
Pathogenesis	• Oxidative damage & opacification of the lens
	• Age >60 • Diabetes mellitus

Cataracts	
Pathogenesis	• Oxidative damage & opacification of the lens
Risk factors	• Age >60 • Diabetes mellitus • Chronic sunlight exposure • Tobacco use • Immunosuppression (eg, HIV, corticosteroids)
Clinical features	• Painless, progressive, bilateral vision loss • Difficulty with nighttime driving • Loss of red reflex • Opacified lens
Treatment	• Artificial lens implantation

This patient has bilateral **opacities in the ocular lenses**, findings consistent with cataracts. **Cataracts** can cause **difficulty with reading** and fine visual tasks; patients often see excessive **glare** at night and **halos** around bright lights due to light scattering in the lens. Examination findings include white or gray cloudiness of the lens, decreased visualization of retinal detail, and loss of the red reflex.

Cataracts are generally related to **chronic photooxidative injury**; the prevalence increases with age, and most patients with cataracts first develop symptoms at age >60. However, cataracts can develop earlier in individuals, such as this patient, with exposure to systemic or ophthalmic **glucocorticoids** (eg, prednisone). This may be due to glucocorticoid-induced transcription of genes in the lens epithelial cell that may alter lens homeostasis or increase the susceptibility to oxidative injury. Other causes of premature cataract formation include diabetes mellitus, ocular trauma, and external radiation exposure.

(Choices A and D) The increased risk of premature cataract formation in patients with systemic lupus erythematosus (SLE) is due primarily to chronic/frequent glucocorticoid exposure, not to the disease itself. Patients with SLE are often treated with hydroxychloroquine; long-term use can cause retinopathy, which presents with decreased central visual acuity, photopsia (flashing lights), and central macular degeneration.

This patient has bilateral **opacities in the ocular lenses**, findings consistent with cataracts. **Cataracts** can cause **difficulty with reading** and fine visual tasks; patients often see excessive **glare** at night and **halos** around bright lights due to light scattering in the lens. Examination findings include white or gray cloudiness of the lens, decreased visualization of retinal detail, and loss of the red reflex.

Cataracts are generally related to **chronic photooxidative injury**; the prevalence increases with age, and most patients with cataracts first develop symptoms at age >60. However, cataracts can develop earlier in individuals, such as this patient, with exposure to systemic or ophthalmic **glucocorticoids** (eg, prednisone). This may be due to glucocorticoid-induced transcription of genes in the lens epithelial cell that may alter lens homeostasis or increase the susceptibility to oxidative injury. Other causes of premature cataract formation include diabetes mellitus, ocular trauma, and external radiation exposure.

(Choices A and D) The increased risk of premature cataract formation in patients with systemic lupus erythematosus (SLE) is due primarily to chronic/frequent glucocorticoid exposure, not to the disease itself. Patients with SLE are often treated with hydroxychloroquine; long-term use can cause retinopathy, which presents with decreased central visual acuity, photopsia (flashing lights), and central macular degeneration.

(Choice B) Excessive, not limited, lifetime sun exposure is associated with an increased risk of cataracts.

(Choice E) Common manifestations of vitamin D deficiency include hypocalcemia, bone pain, and accelerated bone loss. Cataracts are not a major consequence of vitamin D deficiency.

Educational objective:
Cataracts are related primarily to chronic photooxidative injury. Most patients with cataracts first develop symptoms at age >60 but exposure to systemic or ophthalmic glucocorticoids can cause cataracts at an early age. Other causes of premature cataract formation include diabetes mellitus, ocular trauma, and external radiation exposure.

References

- Risk factors for cataracts in systemic lupus erythematosus (SLE).

Pharmacology	Ophthalmology	Corticosteroids
Subject	System	Topic

Copyright © UWorld. All rights reserved.

A 62-year-old man with a history of poor medical follow-up comes to the office due to difficulty seeing. He has had blurry vision for the last 2 weeks. A day ago, he noticed a shadow develop suddenly across the visual field of his right eye. The patient has had no recent headaches, double vision, vertigo, light sensitivity, or nausea. On examination, pupils are equal and reactive to light. Visual field testing by confrontation reveals patchy loss of vision. A flame-shaped retinal hemorrhage in the right eye is noted on funduscopic examination, as shown in the image below.

Which of the following is the most likely cause of his visual disturbance?

A. Central retinal artery occlusion



Which of the following is the most likely cause of his visual disturbance?

- A. Central retinal artery occlusion
- B. Cigarette smoking
- C. Closed-angle glaucoma
- D. Giant cell arteritis
- E. Hyperlipidemia
- F. Hypertension
- G. Migraine
- H. Thyroid eye disease

Submit



Which of the following is the most likely cause of his visual disturbance?

- A. Central retinal artery occlusion (18%)
- B. Cigarette smoking (4%)
- C. Closed-angle glaucoma (4%)
- D. Giant cell arteritis (3%)
- E. Hyperlipidemia (3%)
- ✓ F. Hypertension (66%)
- G. Migraine (0%)
- H. Thyroid eye disease (0%)

Omitted
Correct answer

66%
Answered correctly

05 secs
Time Spent

05/31/2020
Last Updated

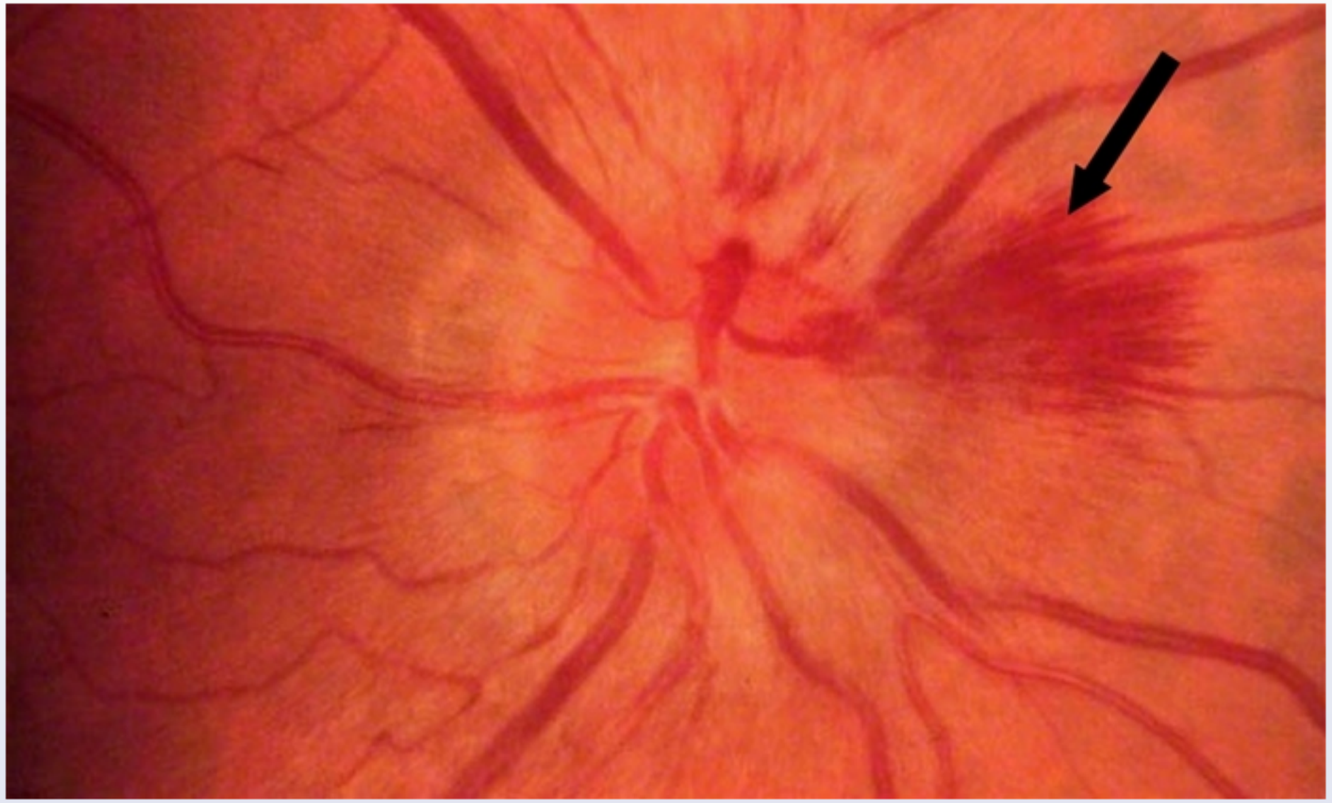

This patient has an acute retinal hemorrhage (arrow), most likely caused by severe, poorly controlled **hypertension**. Hypertensive retinal hemorrhage typically causes painless, unilateral visual disturbances, ranging from mild obscuration without loss of visual acuity to permanent blindness. Severe hypertension in retinal precapillary arterioles causes endothelial disruption, leakage of plasma into the arteriolar wall, and **fibrinous necrosis**. The necrotic vessels can then bleed into the nerve fiber layers, causing dot- and flame-shaped hemorrhages.

Diagnosis of hypertensive retinal hemorrhage is usually confirmed by direct ophthalmoscopic evaluation. Other findings of hypertensive retinopathy include thickening of the arteriolar walls ("copper or silver wiring"), compression of the associated veins (arteriovenous nicking), and small, white foci of retinal ischemia (cotton-wool spots).

This patient has an acute retinal hemorrhage (arrow), most likely caused by severe, poorly controlled **hypertension**. Hypertensive retinal hemorrhage typically causes painless, unilateral visual disturbances, ranging from mild obscuration without loss of visual acuity to permanent blindness. Severe hypertension in retinal precapillary arterioles causes endothelial disruption, leakage of plasma into the arteriolar wall, and **fibrinous necrosis**. The necrotic vessels can then bleed into the nerve fiber layers, causing dot- and flame-shaped hemorrhages.

Diagnosis of hypertensive retinal hemorrhage is usually confirmed by direct ophthalmoscopic evaluation. Other findings of hypertensive retinopathy include thickening of the arteriolar walls ("copper or silver wiring"), compression of the associated veins (arteriovenous nicking), and small, white foci of retinal ischemia (cotton-wool spots).

(Choices A and D) Central retinal artery occlusion is most commonly due to atherosclerosis, cardioembolic disease, or vasculitis (eg, giant cell arteritis). It causes acute monocular vision loss. Examination can reveal a cherry red spot at the macula due to diffuse retinal ischemia, but hemorrhage is not typically seen.

(Choices B and E) Smoking and hyperlipidemia can increase the risk of developing ischemic retinal and optic vascular disease; however, these are not associated with an increased risk of retinal hemorrhage.

(Choice C) Closed-angle glaucoma is characterized by increased intraocular pressure from impaired aqueous humor drainage. It causes acute headache, eye pain, vision loss, and an afferent pupillary defect. Ophthalmoscopic examination reveals cupping of the optic disc without hemorrhage.

(Choice G) Ocular migraine and migraine with visual aura can present with transient visual disturbances, with or without headache. Ophthalmoscopic examination is normal in patients with migraine.

(Choice H) Thyroid eye disease (eg, Graves disease) can present with diplopia and proptosis; however, it is not associated with an increased risk of retinal hemorrhage.

Educational objective:
Severe hypertension in retinal precapillary arterioles causes endothelial disruption, leakage of plasma into the arteriolar wall, and fibrinous necrosis. The necrotic vessels can then bleed into the nerve fiber layer, which can be seen on examination as dot- or flame-shaped hemorrhages.

Pathology Ophthalmology Hypertensive retinopathy

1
2
3
4
5
6
7
8
9
10
11
12
13
14
15
16
17
18
19
20
21

Exhibit Display

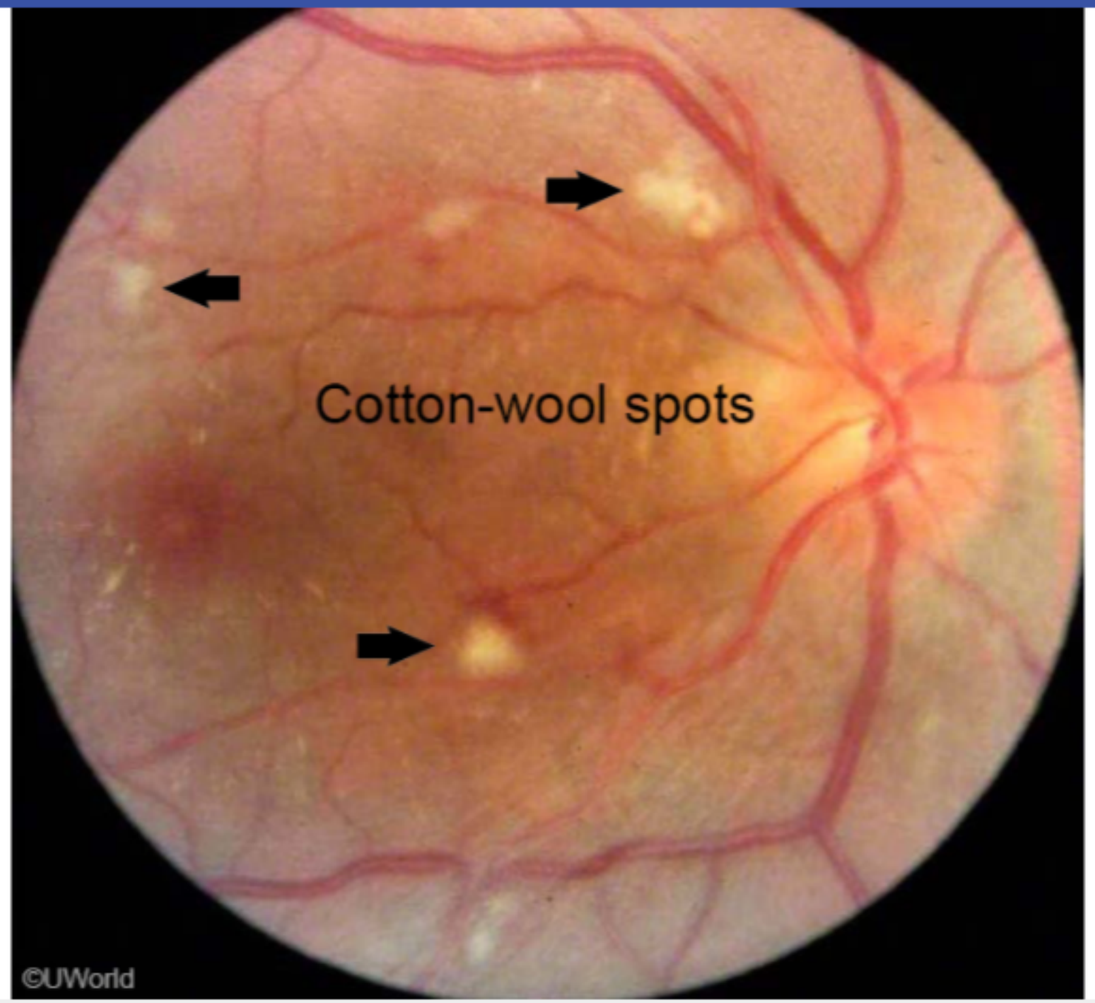

Zoom In | Zoom Out | Reset | Add To New Card | Existing Card

Pathology | Ophthalmology | Hypertensive retinopathy

1
2
3
4
5
6
7
8
9
10
11
12
13
14
15
16
17
18
19
20
21

Exhibit Display

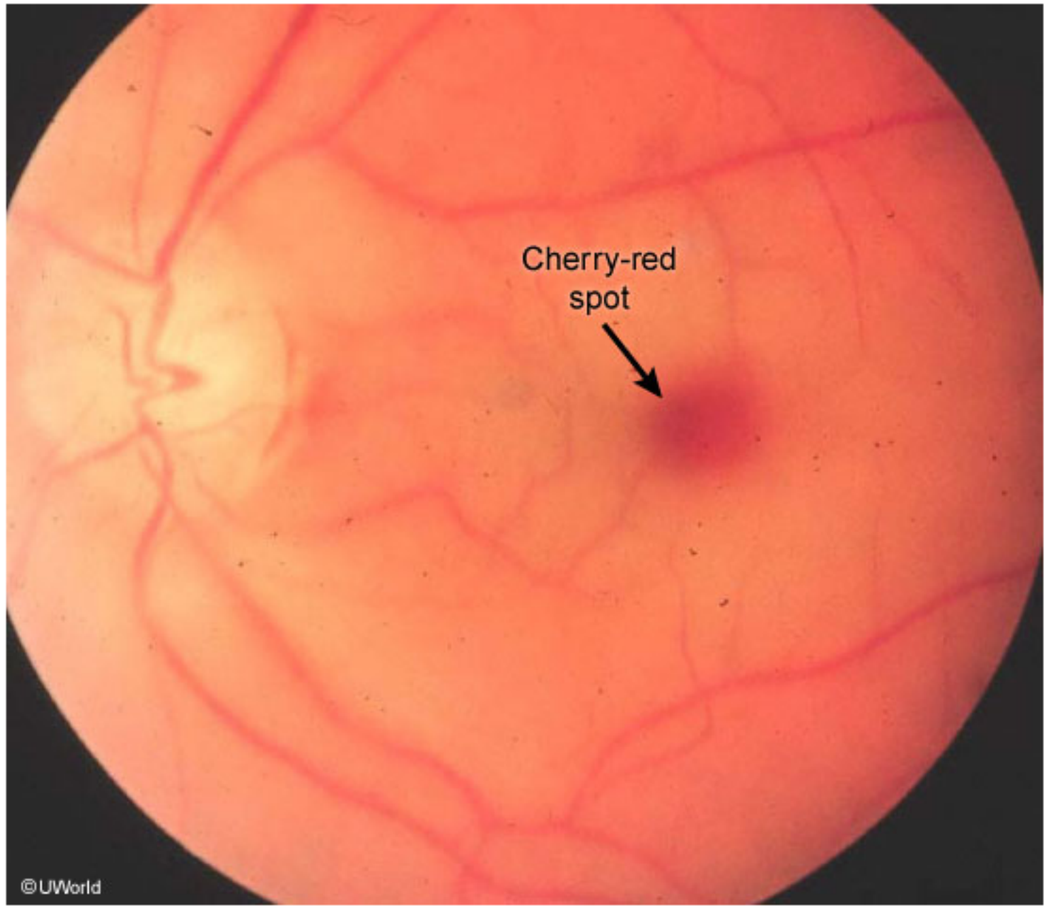

Zoom In | Zoom Out | Reset | Add To New Card | Existing Card

Pathology | Ophthalmology | Hypertensive retinopathy

Exhibit Display

Glaucomatous optic atrophy (advanced)

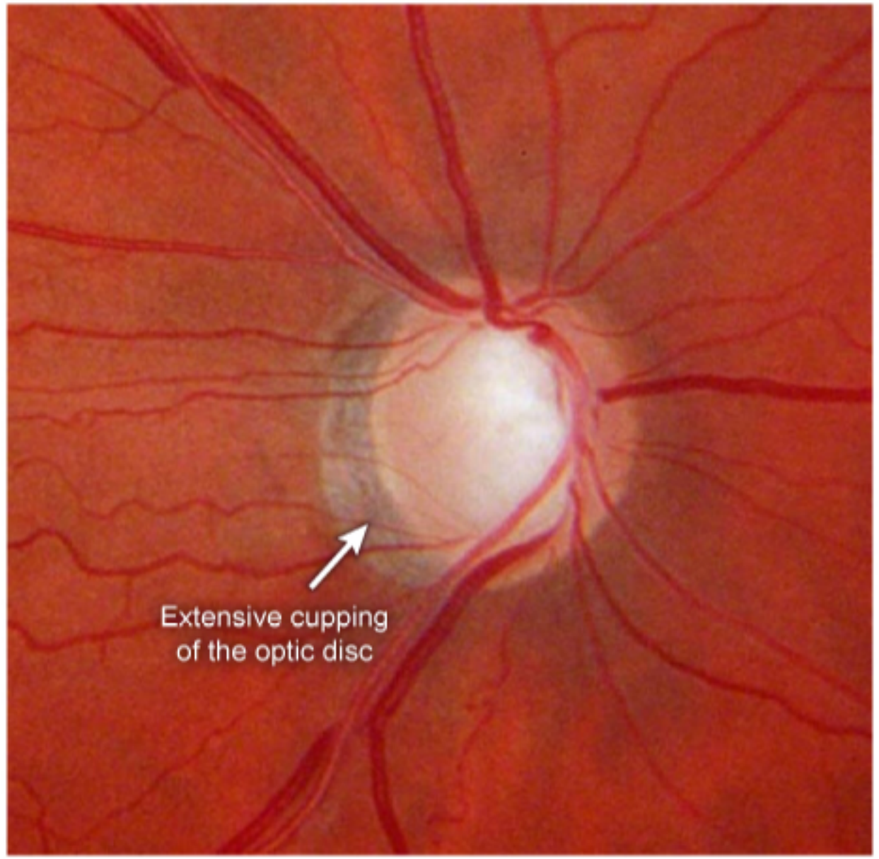

©UWorld

Zoom In Zoom Out Reset Add To New Card | Existing Card

Pathology Ophthalmology Hypertensive retinopathy

A 64-year-old man comes to the emergency department due to painless loss of vision in the right eye. The patient's symptoms started suddenly several hours ago and have persisted. He has had no trauma or any similar episode in the past. He has a history of coronary artery disease, atrial fibrillation, and type 2 diabetes mellitus. Blood pressure is 144/86 mm Hg and pulse is 92/min. Cardiovascular examination reveals irregularly irregular rhythm with no murmurs, no peripheral edema, and slightly diminished pedal pulses in both feet symmetrically. Visual acuity in the right eye is hand motion only and normal in the left eye. Funduscopic examination of the right eye is shown in the image below.

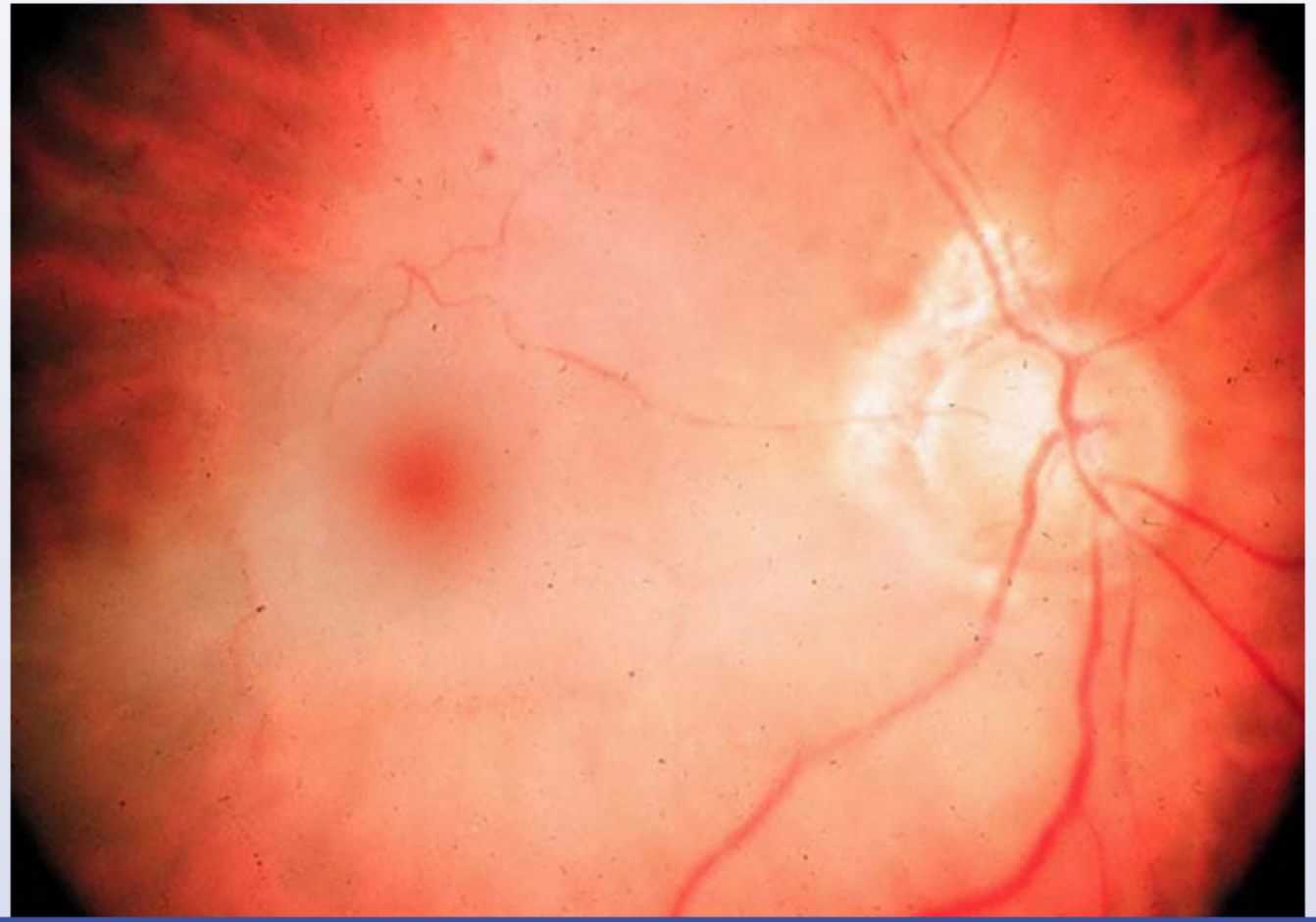

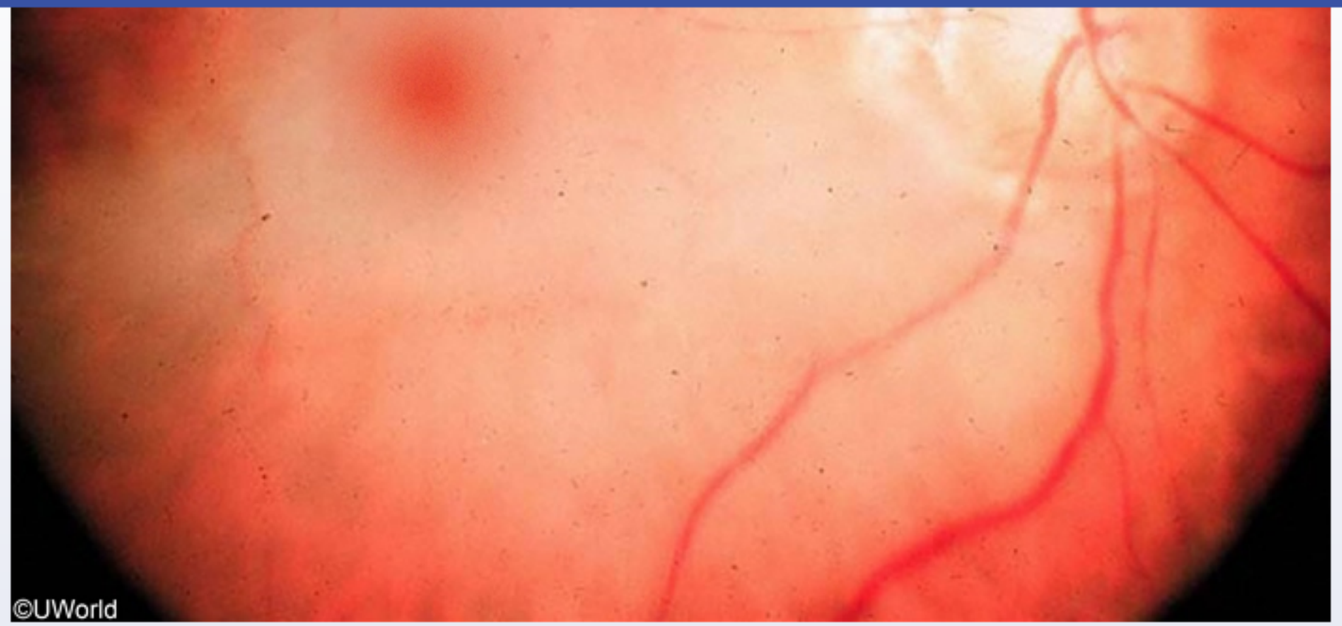

Which of the following is the most likely cause of this patient's loss of vision?

- A. Amaurosis fugax
- B. Diabetic retinopathy
- C. Pituitary adenoma
- D. Retinal artery occlusion
- E. Temporal lobe stroke

Submit

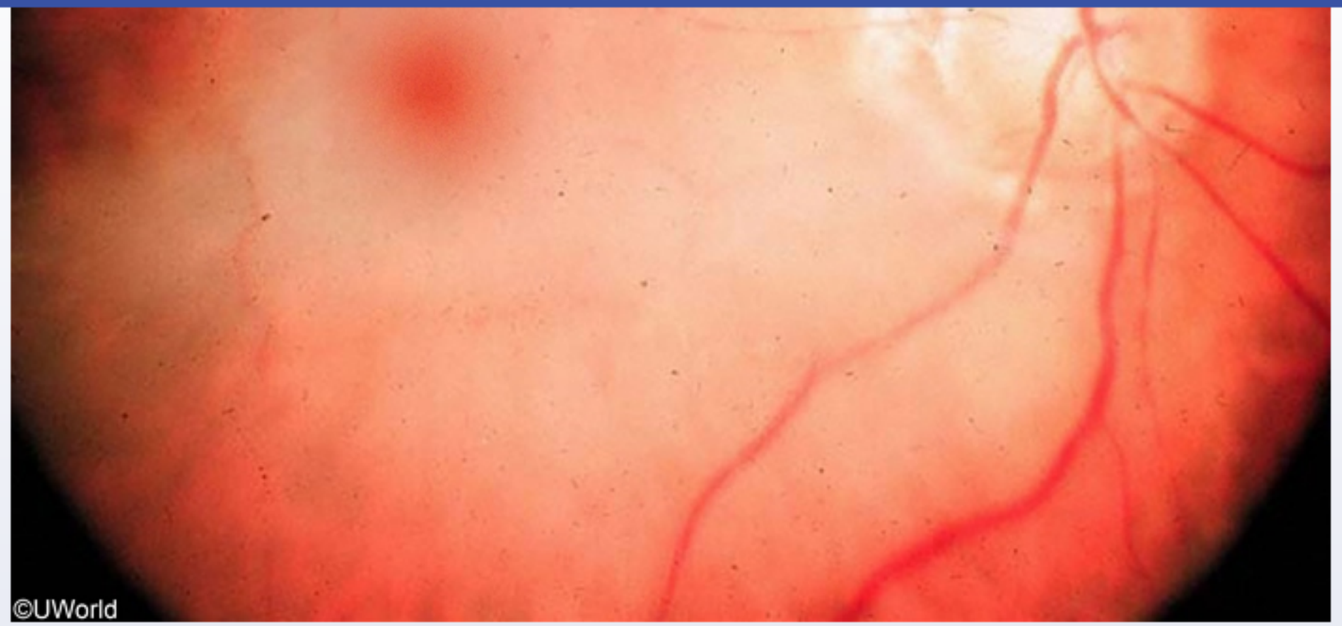

Which of the following is the most likely cause of this patient's loss of vision?

A. Amaurosis fugax (7%)

B. Diabetic retinopathy (14%)

C. Pituitary adenoma (0%)

✓ D. Retinal artery occlusion (76%)

E. Temporal lobe stroke (1%)

Omitted
Correct answer

76%
Answered correctly

04 secs
Time Spent

01/22/2020
Last Updated

Central retinal artery occlusion

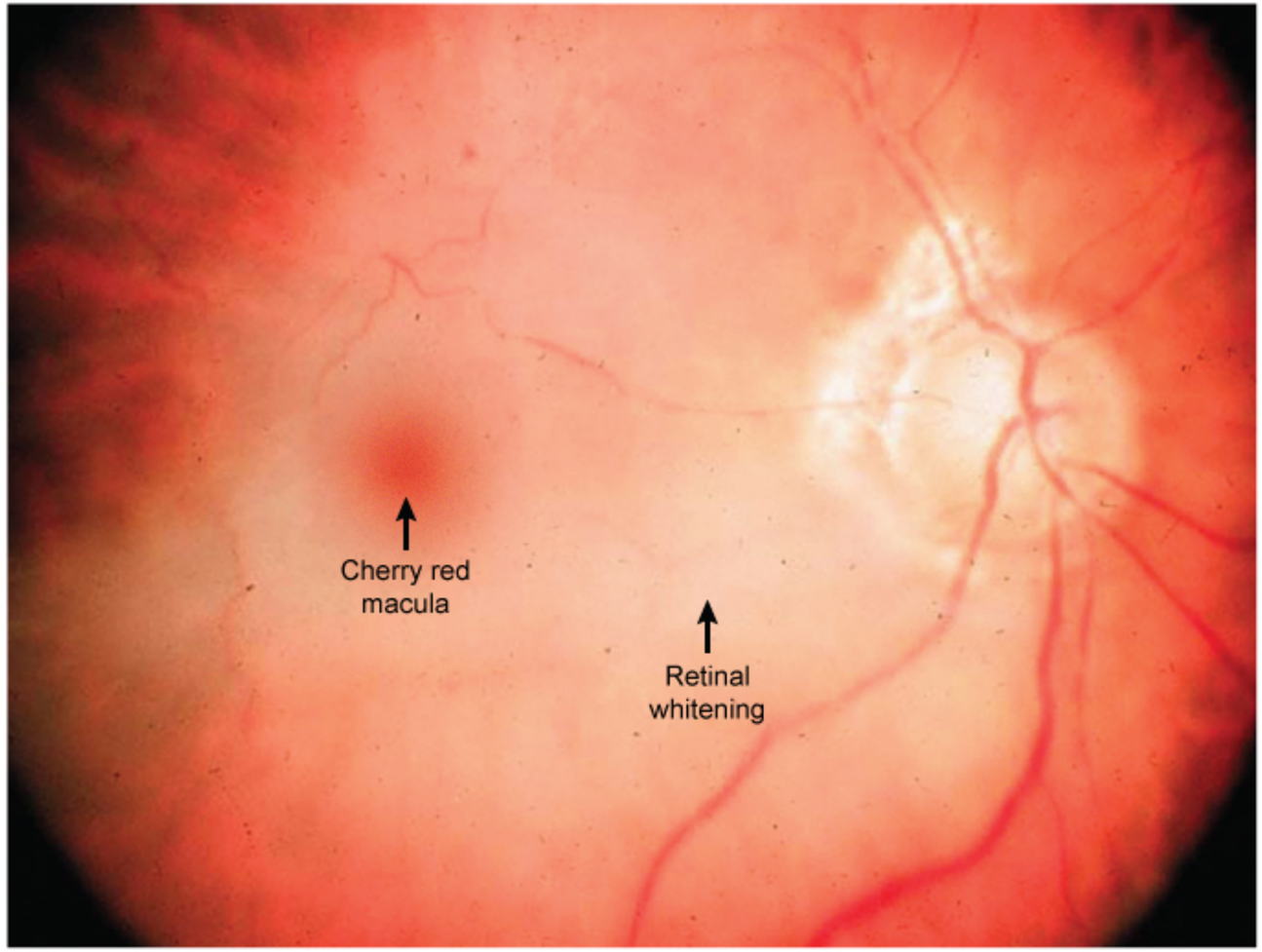

©UWorld

Acute and painless monocular vision loss is characteristic of **central retinal artery occlusion** (CRAO). The vision loss includes the entire visual field and is often permanent. Funduscopic findings include a pale retina (due to ischemia and edema) and a **cherry-red macula** (the fovea and foveola are thin and have a separate blood supply from the choroid artery; the red choroid is easily visible underneath).

©UWorld

Acute and painless monocular vision loss is characteristic of **central retinal artery occlusion** (CRAO). The vision loss includes the entire visual field and is often permanent. Funduscopic findings include a pale retina (due to ischemia and edema) and a **cherry-red macula** (the fovea and foveola are thin and have a separate blood supply from the choroid artery; the red choroid is easily visible underneath).

The central retinal artery is a branch of the ophthalmic artery, which arises from the internal carotid artery. **Athero- and thromboembolism** are the most common causes of CRAO. Predisposing conditions include atrial fibrillation and carotid artery stenosis. CRAO may also be caused by vasculitic diseases (eg, giant cell arteritis).

(Choice A) Amaurosis fugax is a painless, transient, monocular vision loss caused by a small embolus to the ophthalmic artery. It usually does not last more than a few seconds.

(Choice B) Diabetic retinopathy manifests with blurry vision, black spots, floaters, and decreased peripheral vision. Acute visual loss may occur in the setting of a complication such as vitreous hemorrhage, but this patient does not have evidence of neovascularization or hemorrhage.

(Choice C) Large pituitary adenomas may compress the central part of the optic chiasm, causing bitemporal hemianopia.

(Choice E) The lower division of the geniculocalcarine tract (Meyer loop), which carries impulses from the lower retina, passes through the temporal lobe. Temporal lobe infarcts involving the Meyer loop cause contralateral upper quadrantanopsia ("pie in the sky" visual defect).

Educational objective:
Central retinal artery occlusion presents with sudden, painless, and permanent monocular blindness. Funduscopic examination reveals a pale retina and a "cherry-red" macula.

References

- A review of central retinal artery occlusion: clinical presentation and management.

Pathophysiology	Ophthalmology	Retinal artery occlusion
Subject	System	Topic

Copyright © UWorld. All rights reserved.

A 64-year-old African American woman is brought to the clinic by her husband due to a fall. She was walking in her living room when she tripped over an electrical cord. The patient has had several other ground-level falls in the last 6 months but has had no significant injuries. She also gave up driving a year ago following a near-miss motor vehicle accident. Past medical history is notable for hypertension and type 2 diabetes mellitus, for which she takes appropriate medications. Mental status and neurologic examinations are normal. Ophthalmic examination reveals reduced vision in her peripheral visual fields bilaterally and an elevated intraocular pressure. After discussion of treatment options, the patient is initiated on timolol ophthalmic drops. Which of the following structures is the most likely target of this medication?

A. Ciliary epithelium
B. Ciliary muscle
C. Lens
D. Pupil sphincter
E. Trabecular meshwork

Submit

A 64-year-old African American woman is brought to the clinic by her husband due to a fall. She was walking in her living room when she tripped over an electrical cord. The patient has had several other ground-level falls in the last 6 months but has had no significant injuries. She also gave up driving a year ago following a near-miss motor vehicle accident. Past medical history is notable for hypertension and type 2 diabetes mellitus, for which she takes appropriate medications. Mental status and neurologic examinations are normal. Ophthalmic examination reveals reduced vision in her peripheral visual fields bilaterally and an elevated intraocular pressure. After discussion of treatment options, the patient is initiated on timolol ophthalmic drops. Which of the following structures is the most likely target of this medication?

- ✓ A. Ciliary epithelium (42%)
- B. Ciliary muscle (27%)
- C. Lens (0%)
- D. Pupil sphincter (7%)
- E. Trabecular meshwork (20%)

Omitted
Correct answer
A

42%
Answered correctly

02 secs
Time Spent

04/02/2020
Last Updated

Explanation

Glaucoma medications

1
2
3
4
5
6
7
8
9
10
11
12
13
14
15
16
17
18
19
20
21

Glaucoma medications

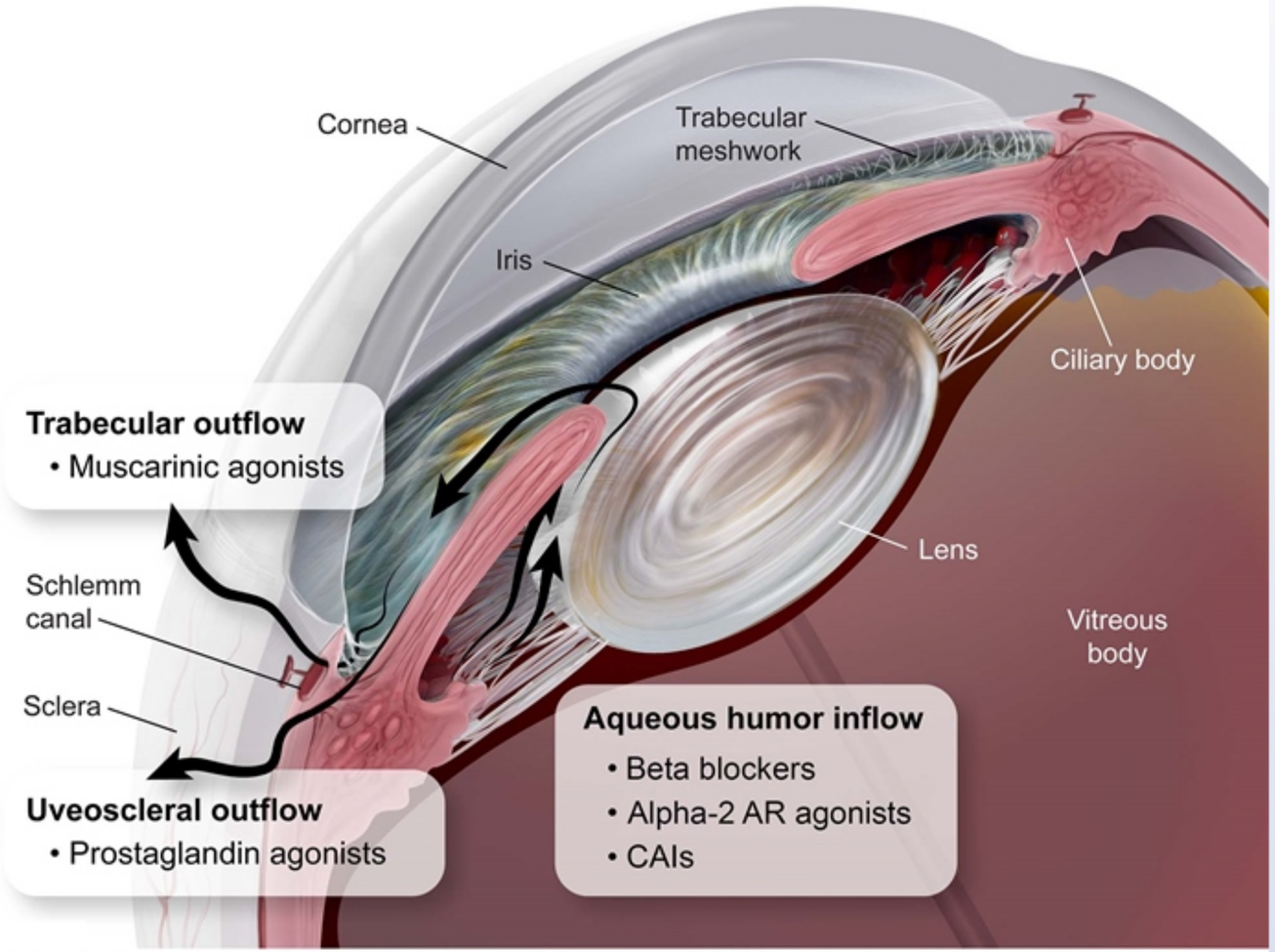

Alpha-2 AR agonists = alpha-2 adrenergic receptor agonists; **CAIs** = carbonic anhydrase inhibitors.

©UWorld

This patient with chronic, progressive loss of peripheral vision has typical features of **open-angle glaucoma**. Glaucoma is a type of **optic**

©UWorld

This patient with chronic, progressive loss of peripheral vision has typical features of **open-angle glaucoma**. Glaucoma is a type of **optic neuropathy** characterized by atrophy of the optic nerve head. It is more common with advancing age and is especially common in certain ethnicities (eg, African Americans). Glaucoma is usually associated with elevated intraocular pressure (IOP) due to increased production or decreased outflow of aqueous humor. **Aqueous humor** is produced by the epithelial cells of the ciliary body. It is secreted into the posterior eye chamber and transferred through the pupil into the anterior eye chamber. The anterior chamber angle (iridocorneal angle) contains a trabecular meshwork through which the aqueous humor diffuses into Schlemm's canal (scleral venous sinus) and subsequently into episcleral and conjunctival veins.

Diagnostic features of glaucoma include elevated IOP and abnormal visual field testing with decreased peripheral vision. Funduscopic examination will show an increased cup-to-disc ratio due to loss of ganglion cell axons. The goal of treatment in glaucoma is to decrease IOP with drugs that either decrease the production of aqueous humor or increase its outflow. Timolol and other nonselective beta blockers work by diminishing the secretion of aqueous humor by the ciliary epithelium.

(Choices B, C, D, and E) The intraocular muscles of the eye, including the ciliary muscle and pupillary sphincter of the iris, receive parasympathetic innervation from cholinergic fibers of the oculomotor nerve (cranial nerve III). Cholinergic agonists (eg, pilocarpine) cause miosis by promoting contraction of the sphincter of the iris. This causes the anterior chamber angle to become wider and makes the trabecular meshwork more accessible to outflow of aqueous humor. Cholinergic agonists also promote ciliary muscle contraction, causing the lens to become more convex.

Educational objective:
Open-angle glaucoma is characterized by progressive loss of peripheral vision from elevated intraocular pressure. Timolol and other nonselective beta blockers work by diminishing the secretion of aqueous humor by the ciliary epithelium. Acetazolamide, a carbonic anhydrase inhibitor, also decreases aqueous humor secretion by the ciliary epithelium. Prostaglandin F2α (eg, latanoprost, travoprost) and cholinomimetics (eg, pilocarpine, carbachol) decrease intraocular pressure by increasing the outflow of aqueous humor.

Pharmacology	Ophthalmology	Glaucoma
Subject	System	Topic

Copyright © UWorld. All rights reserved.

©UWorld

Exhibit Display

Glaucoma pathophysiology

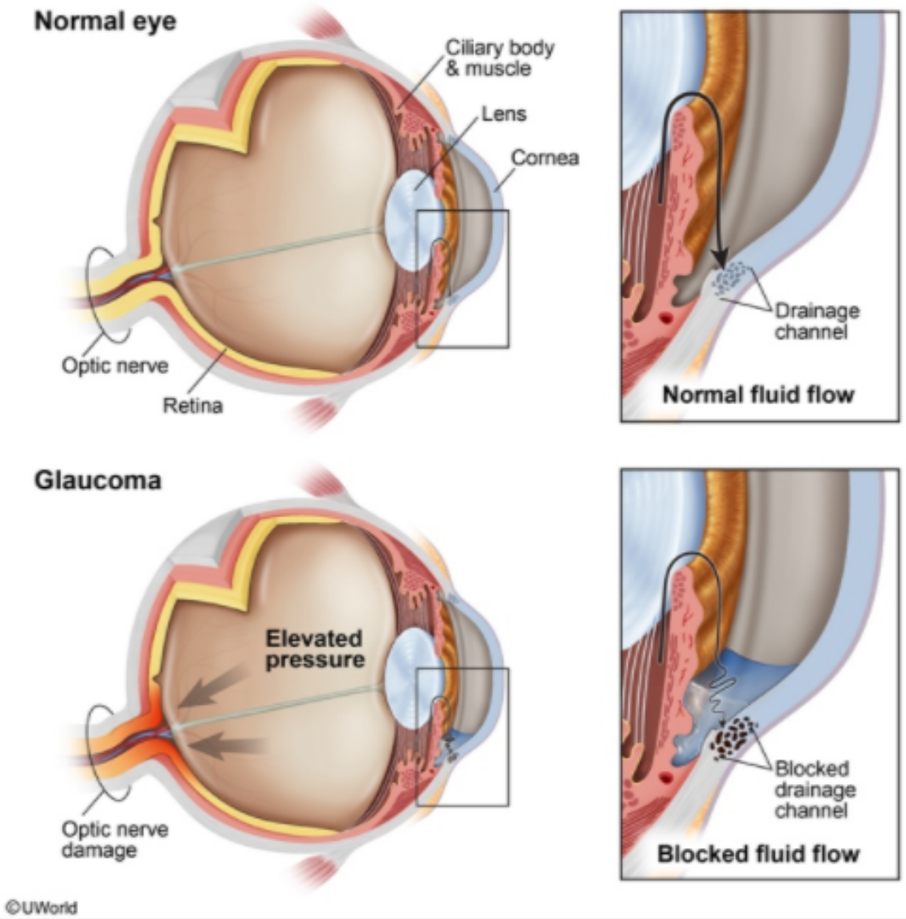

©UWorld

Zoom In | Zoom Out | Reset | Add To New Card | Existing Card

Copyright © UWorld. All rights reserved.

©UWorld

Exhibit Display

Optic disc in glaucoma

Normal	Open-angle glaucoma
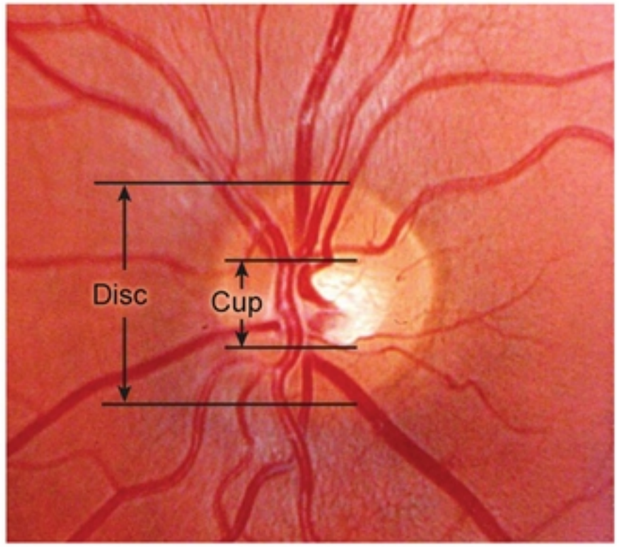	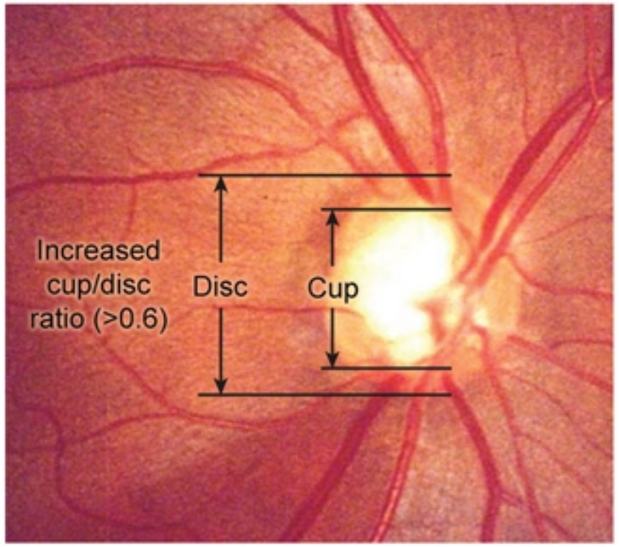
• Cup/disc ratio <0.5 • Clear disc rim	• Enlarged cup with cup/disc ratio >0.6 • Increase in cup size over time • Thinning of disc rim • Pale disc (optic nerve atrophy)

©UWorld

Zoom In | Zoom Out | Reset | Add To New Card | Existing Card

Copyright © UWorld. All rights reserved.

A 3-month-old boy is brought to the office by his mother for a routine checkup. He is found to have a right-sided white pupillary reflex. His father was diagnosed with a retinal neoplasm during childhood and had his left eye enucleated. This child is at the greatest risk of developing which of the following neoplasms?

A. Acute lymphoblastic leukemia
B. Neuroblastoma
C. Ewing sarcoma
D. Osteosarcoma
E. Medulloblastoma

Submit

A 3-month-old boy is brought to the office by his mother for a routine checkup. He is found to have a right-sided white pupillary reflex. His father was diagnosed with a retinal neoplasm during childhood and had his left eye enucleated. This child is at the greatest risk of developing which of the following neoplasms?

- A. Acute lymphoblastic leukemia (2%)
- B. Neuroblastoma (22%)
- C. Ewing sarcoma (5%)
- ✓ D. Osteosarcoma (62%)
- E. Medulloblastoma (6%)

Omitted
Correct answer
D

62%
Answered correctly

02 secs
Time Spent

04/05/2020
Last Updated

Explanation

Knudson's 2-hit hypothesis

Both copies of the gene must be knocked out to promote malignancy.

Sporadic cancer:
2 acquired mutations

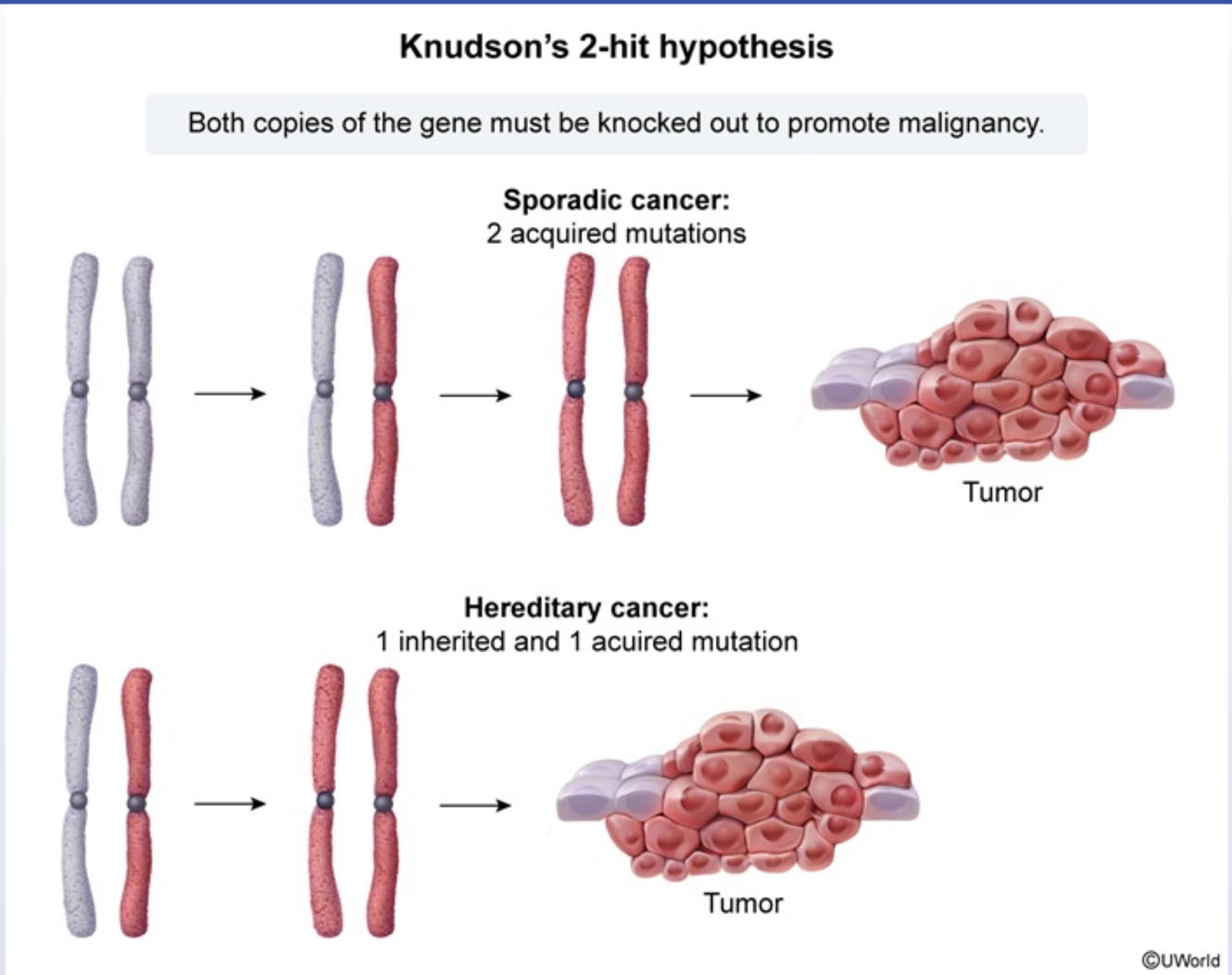

Retinoblastoma is the most common ocular tumor of childhood. It usually presents with a white pupillary reflex (leukocoria) in children <5 years old. Approximately 60% of retinoblastomas are sporadic (usually unilateral), while **40% are familial** (often, but not always, bilateral).

Familial retinoblastoma occurs due to a **germline mutation** that affects the **Rb tumor suppressor gene** on chromosome 13; affected children

Retinoblastoma is the most common ocular tumor of childhood. It usually presents with a white pupillary reflex (leukocoria) in children <5 years old. Approximately 60% of retinoblastomas are sporadic (usually unilateral), while **40% are familial** (often, but not always, bilateral).

Familial retinoblastoma occurs due to a **germline mutation** that affects the **Rb tumor suppressor gene** on chromosome 13; affected children carry one copy of the mutation in all their cells. However, there are two copies of the Rb gene (one allele from each parent), and malignancy does not occur while at least one copy of the gene is still functional. A somatic second mutation acquired early in life is the "**second hit**" that leads to retinoblastoma, as cells with **two inactivated Rb genes** proliferate uncontrollably and give rise to **malignancy**.

Children with familial retinoblastoma often acquire other "second hit" mutations later in life, leading to additional tumors, usually sarcomas such as **osteosarcoma**. In contrast, patients with sporadic retinoblastoma are not at risk for other malignancies, as the chance of two acquired somatic mutations occuring multiple times in different cell lineages is very low.

(Choice A) Patients with Down syndrome, ataxia-telangiectasia, and neurofibromatosis type 1 have an increased risk of development of acute lymphoblastic leukemia, which is not associated with familial retinoblastoma.

(Choice B) Neuroblastoma is a common childhood cancer that arises from sympathetic nervous tissue, most commonly in the adrenals. Most cases are sporadic.

(Choice C) Ewing sarcoma is an undifferentiated neoplasm of mesenchymal origin that most commonly occurs in the long and flat bones of children and adolescents. It occurs sporadically.

(Choice E) Medulloblastoma is the most common *malignant* brain tumor of childhood, typically arising in the cerebellum.

Educational objective:
Familial retinoblastoma occurs as a result of mutations of each of the two Rb genes ("two hits"). These patients have an increased risk of secondary tumors, especially osteosarcomas, later in life.

Pathology	Ophthalmology	Retinoblastoma
Subject	System	Topic

Copyright © UWorld. All rights reserved.

A 4-year-old girl is brought to the clinic due to an inward deviated right eye. Examination shows a pale red reflex in the right eye relative to the left eye. Dilated funduscopic examination reveals a well-circumscribed white mass within the retina. Genetic analysis shows a germline mutation in the patient's cells leading to development of the mass. Which of the following is the most likely function of the protein affected by this patient's gene mutation?

A. Activation of receptor tyrosine kinase

B. Conversion of GTP to GDP

C. Opposition of p53 activity

D. Prevention of the G1/S cell cycle transition

E. Repair of damaged DNA

Submit

A 4-year-old girl is brought to the clinic due to an inward deviated right eye. Examination shows a pale red reflex in the right eye relative to the left eye. Dilated funduscopic examination reveals a well-circumscribed white mass within the retina. Genetic analysis shows a germline mutation in the patient's cells leading to development of the mass. Which of the following is the most likely function of the protein affected by this patient's gene mutation?

- A. Activation of receptor tyrosine kinase (1%)
- B. Conversion of GTP to GDP (9%)
- C. Opposition of p53 activity (8%)
- ✓ D. Prevention of the G1/S cell cycle transition (74%)
- E. Repair of damaged DNA (5%)

Omitted
Correct answer
D

Collecting Statistics

02 secs
Time Spent

07/09/2020
Last Updated

Explanation

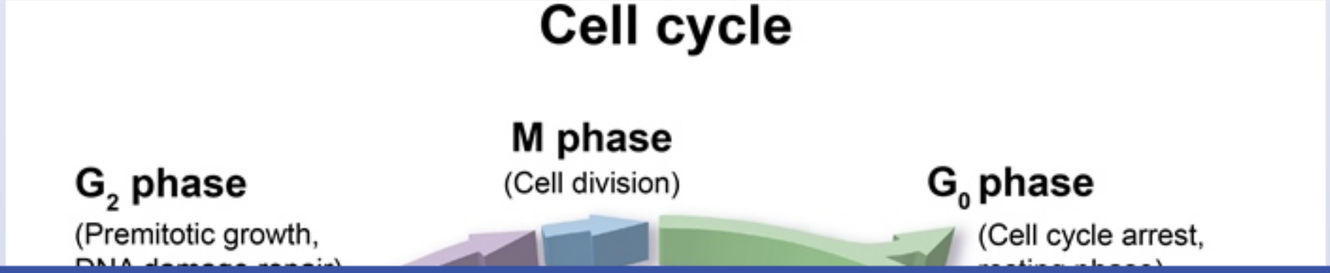

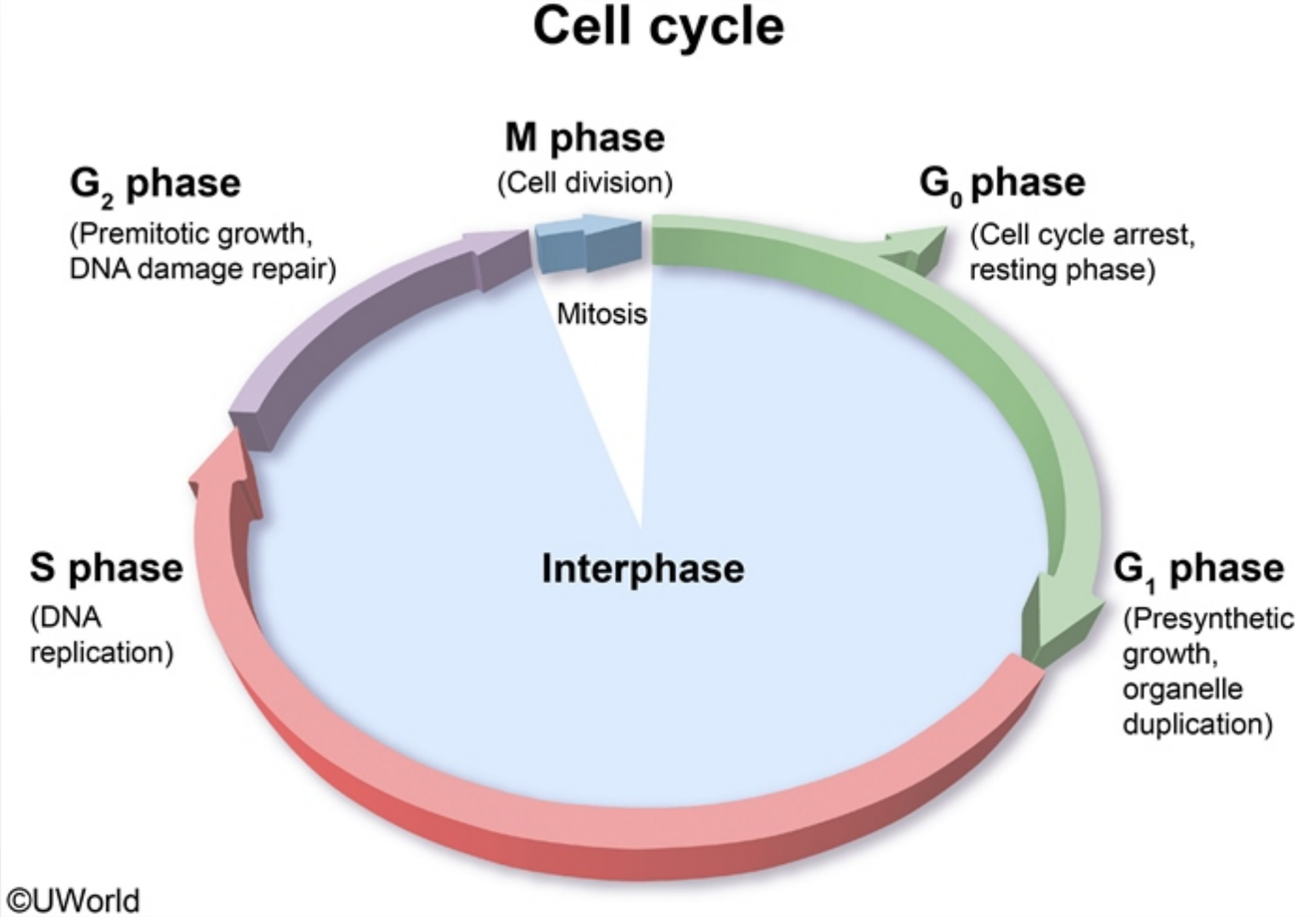

This patient's pale red reflex and well-circumscribed white mass within the retina are indicative of **retinoblastoma**. Retinoblastoma is an intraocular tumor caused by inactivating mutations affecting the ***RB1* tumor suppressor gene** with subsequent dysregulation of the cell cycle.

The cell cycle consists of the following stages:

- Gap phase 0 (G0 phase) is a resting stage in which the cell cycle is suspended.

The cell cycle consists of the following stages:

- Gap phase 0 (G0 phase) is a resting stage in which the cell cycle is suspended.
- Interphase is the stage in which the cell prepares for division. Interphase is subdivided into the G1 phase (synthesis of RNA, protein, lipid, and carbohydrate), S phase (DNA replication), and the G2 phase (ATP synthesis).
- Mitosis (M) is the stage in which the cell divides into two daughter cells.

Checkpoints occur at the G1/S and G2/M transitions, allowing the cell cycle to be stopped if damaged DNA is detected by cyclins and cyclin-dependent kinases. DNA repair mechanisms are activated, but if the DNA damage is too substantial, the cell undergoes apoptosis.

The ***RB1* gene** encodes the Rb protein that regulates the **G1/S checkpoint**. In its active form, Rb protein binds and inhibits E2F transcription factors, thereby halting the cell cycle. In contrast, when a cell is ready to divide, Rb protein is phosphorylated by cyclin-dependent kinases, allowing the cell to proceed through the G1/S checkpoint. **Loss-of-function** mutations affecting the Rb protein result in unrestricted progression through the G1/S checkpoint, leading to **uncontrolled cell division**. Inciting *RB1* mutations have been linked to retinoblastoma and **osteosarcoma**.

(Choice A) Many receptor tyrosine kinases have stimulatory effects on cell growth, and increased receptor activity occurs with a variety of cancers. For example, overexpression of *EGFR* and *MET* are associated with non–small cell lung cancer, and *HER2* is associated with breast cancer.

(Choice B) Abnormal K-Ras GTPase function due to a *KRAS* mutation prevents the conversion of GTP to GDP, which results in constant activation of the MAPK pathway and uncontrolled cellular proliferation. *KRAS* mutations are associated with lung and colorectal cancers, not retinoblastoma.

(Choice C) Tumor suppressor protein p53 arrests the cell cycle at the G1/S checkpoint if DNA damage is detected and initiates cell apoptosis if DNA repair fails. Mutations of p53 are associated with most cancers, particularly Li-Fraumeni syndrome (sarcoma, breast, leukemia, and adrenal cancers). *RB1* and p53 are both critical components of tumor suppression pathways, and their normal function complements one another to prevent cancer progression.

(Choice E) *BRCA1* and *BRCA2* are two of many DNA repair genes that have been identified. When mutated, these genes are associated with an

- Gap phase 0 (G0 phase) is a resting stage in which the cell cycle is suspended.
- Interphase is the stage in which the cell prepares for division. Interphase is subdivided into the G1 phase (synthesis of RNA, protein, lipid, and carbohydrate), S phase (DNA replication), and the G2 phase (ATP synthesis).
- Mitosis (M) is the stage in which the cell divides into two daughter cells.

Checkpoints occur at the G1/S and G2/M transitions, allowing the cell cycle to be stopped if damaged DNA is detected by cyclins and cyclin-dependent kinases. DNA repair mechanisms are activated, but if the DNA damage is too substantial, the cell undergoes apoptosis.

The ***RB1* gene** encodes the Rb protein that regulates the **G1/S checkpoint**. In its active form, Rb protein binds and inhibits E2F transcription factors, thereby halting the cell cycle. In contrast, when a cell is ready to divide, Rb protein is phosphorylated by cyclin-dependent kinases, allowing the cell to proceed through the G1/S checkpoint. **Loss-of-function** mutations affecting the Rb protein result in unrestricted progression through the G1/S checkpoint, leading to **uncontrolled cell division**. Inciting *RB1* mutations have been linked to retinoblastoma and **osteosarcoma**.

(Choice A) Many receptor tyrosine kinases have stimulatory effects on cell growth, and increased receptor activity occurs with a variety of cancers. For example, overexpression of *EGFR* and *MET* are associated with non–small cell lung cancer, and *HER2* is associated with breast cancer.

(Choice B) Abnormal K-Ras GTPase function due to a *KRAS* mutation prevents the conversion of GTP to GDP, which results in constant activation of the MAPK pathway and uncontrolled cellular proliferation. *KRAS* mutations are associated with lung and colorectal cancers, not retinoblastoma.

(Choice C) Tumor suppressor protein p53 arrests the cell cycle at the G1/S checkpoint if DNA damage is detected and initiates cell apoptosis if DNA repair fails. Mutations of p53 are associated with most cancers, particularly Li-Fraumeni syndrome (sarcoma, breast, leukemia, and adrenal cancers). *RB1* and p53 are both critical components of tumor suppression pathways, and their normal function complements one another to prevent cancer progression.

(Choice E) *BRCA1* and *BRCA2* are two of many DNA repair genes that have been identified. When mutated, these genes are associated with an increased risk of breast and ovarian cancer.

Educational objective:

1
2
3
4
5
6
7
8
9
10
11
12
13
14
15
16
17
18
19
20
21

- Gap phase 0 (G0 phase) is a resting stage in which the cell cycle is suspended.

Exhibit Display

KRAS mutation causing anti-EGFR resistance

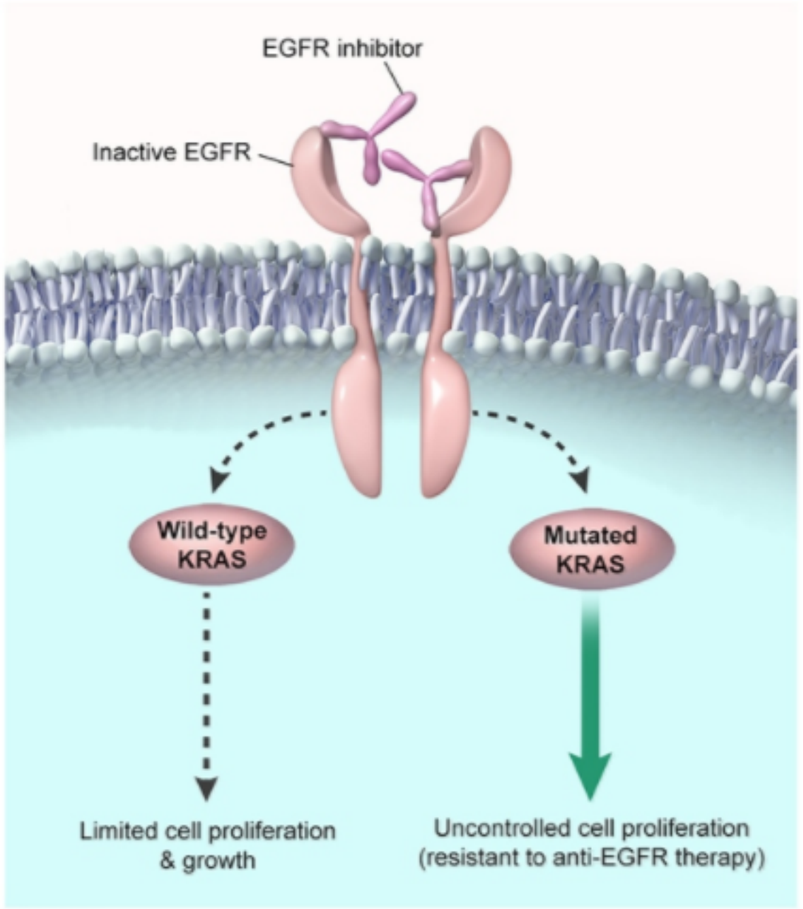

©UWorld

Zoom In | Zoom Out | Reset | Add To New Card | Existing Card

Educational objective:

(Choice A) Many receptor tyrosine kinases have stimulatory effects on cell growth, and increased receptor activity occurs with a variety of cancers. For example, overexpression of *EGFR* and *MET* are associated with non–small cell lung cancer, and *HER2* is associated with breast cancer.

(Choice B) Abnormal K-Ras GTPase function due to a *KRAS* mutation prevents the conversion of GTP to GDP, which results in constant activation of the MAPK pathway and uncontrolled cellular proliferation. *KRAS* mutations are associated with lung and colorectal cancers, not retinoblastoma.

(Choice C) Tumor suppressor protein p53 arrests the cell cycle at the G1/S checkpoint if DNA damage is detected and initiates cell apoptosis if DNA repair fails. Mutations of p53 are associated with most cancers, particularly Li-Fraumeni syndrome (sarcoma, breast, leukemia, and adrenal cancers). *RB1* and p53 are both critical components of tumor suppression pathways, and their normal function complements one another to prevent cancer progression.

(Choice E) *BRCA1* and *BRCA2* are two of many DNA repair genes that have been identified. When mutated, these genes are associated with an increased risk of breast and ovarian cancer.

Educational objective:
Retinoblastoma is associated with inactivating mutations of the *RB1* tumor suppressor gene, which normally restricts cells from passing the G1/S checkpoint until the cell is ready to divide. Impaired function of the Rb protein allows unrestricted progression through the G1/S checkpoint, leading to uncontrolled cell division.

References

- Molecular mechanisms underlying RB protein function.
- RB and cell cycle progression.

Pathology	Ophthalmology	Retinoblastoma
Subject	System	Topic

Copyright © UWorld. All rights reserved.

A 43-year-old man comes to the emergency department due to painless, progressive visual impairment. The patient was diagnosed with sexually acquired HIV infection 4 years ago. He was previously started on antiretroviral therapy but has been noncompliant with his prescribed medications. His most recent CD4 count was 37 cells/mm^3. Physical examination shows no skin rash or corneal lesions. Funduscopy reveals the findings seen in the image below.

Which of the following medications is the best initial therapy for this patient?

1
2
3
4
5
6
7
8
9
10
11
12
13
14
15
16
17
18
19
20
21

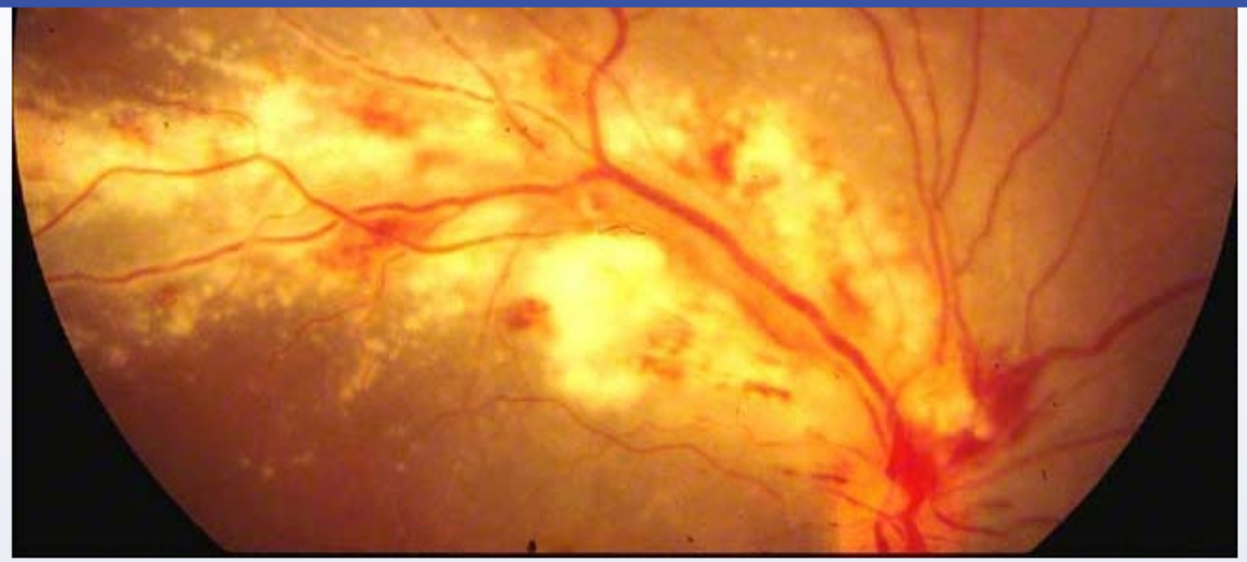

Which of the following medications is the best initial therapy for this patient?

- A. Acyclovir
- B. Amphotericin B
- C. Clarithromycin
- D. Flucytosine
- E. Ganciclovir
- F. Penicillin G

Submit

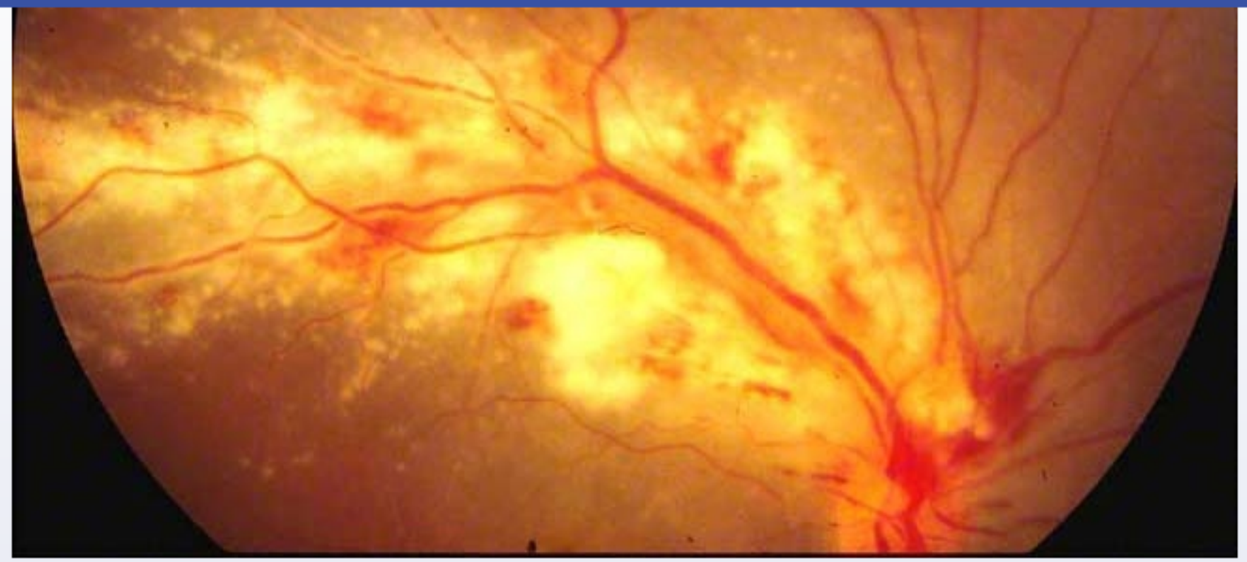

Which of the following medications is the best initial therapy for this patient?

- A. Acyclovir (10%)
- B. Amphotericin B (6%)
- C. Clarithromycin (3%)
- D. Flucytosine (3%)
- ✓ E. Ganciclovir (74%)
- F. Penicillin G (1%)

Omitted
Correct answer

74%
Answered correctly

05 secs
Time Spent

07/05/2020
Last Updated

1
2
3
4
5
6
7
8
9
10
11
12
13
14
15
16
17
18
19
20
21

Black arrows = retinal hemorrhage; **White arrows** = CMV granular retinal lesions.
©UWorld

Patients with untreated AIDS who have CD4 counts <50/mm^3 are at high risk for **cytomegalovirus (CMV) retinitis**. Suspicion is often raised when a patient with advanced AIDS develops slowly progressive **blurred vision**, scotoma (blind spots), floaters, or photopsia (flashing lights). Although most cases are thought to arise due to hematogenous dissemination of CMV, serum testing for the virus is often (~50%) negative.

Black arrows = retinal hemorrhage; **White arrows** = CMV granular retinal lesions.
©UWorld

Patients with untreated AIDS who have CD4 counts <50/mm^3 are at high risk for **cytomegalovirus (CMV) retinitis**. Suspicion is often raised when a patient with advanced AIDS develops slowly progressive **blurred vision**, scotoma (blind spots), floaters, or photopsia (flashing lights). Although most cases are thought to arise due to hematogenous dissemination of CMV, serum testing for the virus is often (~50%) negative. Therefore, the diagnosis is typically established when funduscopy reveals **yellow-white**, **fluffy retinal lesions** near the retinal vessels associated with **hemorrhage**.

Treatment is required to prevent progression and blindness. **Ganciclovir**, a guanine nucleoside analogue that is structurally similar to acyclovir but expresses greater activity against CMV DNA polymerase, is first-line therapy. Patients are also typically started on antiretroviral therapy to increase CD4 count. A major complication of CMV retinitis is retinal detachment due to the replacement of damaged retina with thin, atrophic scar tissue (which is prone to tear).

(Choice A) Acyclovir is used to treat herpes simplex (HSV) and varicella zoster virus (VZV) infections. Although these infections occasionally cause acute retinal necrosis, most cases arise in older, immunocompetent individuals (not patients with advanced AIDS). In addition, HSV retinitis and VZV retinitis are usually associated with significant vitreal inflammation, spotty peripheral retinal lesions, and infrequent hemorrhage.

(Choice B) *Candida* endophthalmitis is treated with amphotericin B. Funduscopy usually reveals focal, white, mound-like lesions on the retina. Most cases occur in the setting of an indwelling central venous catheter or total parenteral nutrition.

(Choice C) Clarithromycin is used in conjunction with other antibiotics for the treatment of *Mycobacterium avium* complex infection, which usually causes fever, night sweats, abdominal pain, and diarrhea.

(Choice D) *Cryptococcus neoformans* infections are treated with flucytosine, a fluorinated analog of cytosine, in combination with amphotericin B. Although cryptococcal endophthalmitis can occur in patients with advanced AIDS, it is much less common than CMV retinitis, and patients often have other manifestations of cryptococcal infection such as skin lesions or meningoencephalitis.

(Choice F) Penicillin G is used to treat ocular (and neuro-) syphilis. Ocular syphilis often presents as uveitis but can cause retinitis, which usually appears as ground-glass lesions with significant vitreal inflammation. Most patients also have manifestations of syphilitic meningitis (eg, headache, vomiting).

Educational objective:

but expresses greater activity against CMV DNA polymerase, is first-line therapy. Patients are also typically started on antiretroviral therapy to increase CD4 count. A major complication of CMV retinitis is retinal detachment due to the replacement of damaged retina with thin, atrophic scar tissue (which is prone to tear).

(Choice A) Acyclovir is used to treat herpes simplex (HSV) and varicella zoster virus (VZV) infections. Although these infections occasionally cause acute retinal necrosis, most cases arise in older, immunocompetent individuals (not patients with advanced AIDS). In addition, HSV retinitis and VZV retinitis are usually associated with significant vitreal inflammation, spotty peripheral retinal lesions, and infrequent hemorrhage.

(Choice B) *Candida* endophthalmitis is treated with amphotericin B. Funduscopy usually reveals focal, white, mound-like lesions on the retina. Most cases occur in the setting of an indwelling central venous catheter or total parenteral nutrition.

(Choice C) Clarithromycin is used in conjunction with other antibiotics for the treatment of *Mycobacterium avium* complex infection, which usually causes fever, night sweats, abdominal pain, and diarrhea.

(Choice D) *Cryptococcus neoformans* infections are treated with flucytosine, a fluorinated analog of cytosine, in combination with amphotericin B. Although cryptococcal endophthalmitis can occur in patients with advanced AIDS, it is much less common than CMV retinitis, and patients often have other manifestations of cryptococcal infection such as skin lesions or meningoencephalitis.

(Choice F) Penicillin G is used to treat ocular (and neuro-) syphilis. Ocular syphilis often presents as uveitis but can cause retinitis, which usually appears as ground-glass lesions with significant vitreal inflammation. Most patients also have manifestations of syphilitic meningitis (eg, headache, vomiting).

Educational objective:
Cytomegalovirus retinitis is the most common cause of ocular disease in patients with untreated AIDS who have CD4 counts <50/mm^3. Diagnosis is made by funduscopy, which typically reveals yellow-white, fluffy retinal lesions near the retinal vessels with associated hemorrhage. Treatment with ganciclovir is required to prevent blindness.

Pharmacology	Ophthalmology	Cytomegalovirus
Subject	System	Topic

Copyright © UWorld. All rights reserved.

A 67-year-old smoker comes to the office with a 2-week history of decreased vision in his right eye that he describes as "blurry" and "distorted." The patient has been having vision problems over the past year, and these have made it more difficult to drive and require that he use a bright light to read the newspaper. He has no history of diabetes mellitus or hypertension. The patient uses an albuterol inhaler for occasional wheezing and shortness of breath. Ophthalmologic examination of the right eye shows a grayish discoloration of the macula with areas of adjacent hemorrhage. Which of the following should be specifically targeted in treatment of this patient's condition?

A. CD20 lymphocyte glycoprotein

B. Epidermal growth factor receptor

C. Interleukin-2

D. Tumor necrosis factor-alpha

E. Vascular endothelial growth factor

Submit

A 67-year-old smoker comes to the office with a 2-week history of decreased vision in his right eye that he describes as "blurry" and "distorted." The patient has been having vision problems over the past year, and these have made it more difficult to drive and require that he use a bright light to read the newspaper. He has no history of diabetes mellitus or hypertension. The patient uses an albuterol inhaler for occasional wheezing and shortness of breath. Ophthalmologic examination of the right eye shows a grayish discoloration of the macula with areas of adjacent hemorrhage. Which of the following should be specifically targeted in treatment of this patient's condition?

A. CD20 lymphocyte glycoprotein (1%)

B. Epidermal growth factor receptor (6%)

C. Interleukin-2 (3%)

D. Tumor necrosis factor-alpha (6%)

✓ E. Vascular endothelial growth factor (82%)

Omitted
Correct answer
E

82%
Answered correctly

01 sec
Time Spent

04/12/2020
Last Updated

Explanation

This patient likely has **age-related macular degeneration (AMD)**, the leading cause of blindness in industrialized countries. AMD occurs in genetically predisposed individuals as a result of advancing age and environmental factors (eg, smoking) and is classified into dry and wet subtypes. **Dry AMD** is characterized by **gradual** vision loss in one or both eyes and can cause difficulty with driving/reading. The condition likely results from chronic oxidative damage to the retinal pigment epithelium and choriocapillaris, leading to subretinal inflammation with abnormal extracellular matrix formation (eg, confluent drusen, basement membrane thickening). These changes appear on funduscopy as subretinal drusen

This patient likely has **age-related macular degeneration (AMD)**, the leading cause of blindness in industrialized countries. AMD occurs in genetically predisposed individuals as a result of advancing age and environmental factors (eg, smoking) and is classified into dry and wet subtypes. **Dry AMD** is characterized by **gradual** vision loss in one or both eyes and can cause difficulty with driving/reading. The condition likely results from chronic oxidative damage to the retinal pigment epithelium and choriocapillaris, leading to subretinal inflammation with abnormal extracellular matrix formation (eg, confluent drusen, basement membrane thickening). These changes appear on funduscopy as subretinal drusen deposits with pigment abnormalities.

Progressive extracellular matrix accumulation can eventually result in retinal hypoxia, which stimulates local vascular endothelial growth factor (VEGF) production and causes subretinal neovascularization with formation of leaky vessels. This condition is termed **wet AMD** and presents with **acute** vision loss (days to weeks) with **metamorphopsia** (distortion of straight lines). Funduscopy shows a grayish-green subretinal discoloration with adjacent fluid/hemorrhage.

Patients with dry or wet AMD may benefit from antioxidant vitamins and zinc, and smokers should receive **smoking cessation** counseling to prevent disease progression. Wet AMD usually requires specific treatment with **VEGF inhibitors** (eg, ranibizumab, bevacizumab).

(Choice A) Therapy against the CD20 glycoprotein on B cells (eg, the monoclonal antibody rituximab) is used to treat various lymphomas and active rheumatoid arthritis.

(Choice B) Epidermal growth factor receptor inhibitors (eg, erlotinib, gefitinib) are used to treat advanced non-small cell lung cancer.

(Choice C) Anti-interleukin-2 therapy is primarily used for immunosuppression in organ transplant patients and in conditions such as graft versus host disease.

(Choice D) Inhibitors of tumor necrosis factor-alpha are used in many inflammatory autoimmune conditions, such as rheumatoid arthritis, inflammatory bowel disease, and seronegative spondyloarthropathies.

Educational objective:
Wet age-related macular degeneration is characterized by retinal neovascularization due to increased vascular endothelial growth factor (VEGF) levels. Patients typically have acute vision loss and metamorphopsia with funduscopy showing a grayish-green subretinal membrane and/or subretinal hemorrhage. Treatment includes smoking cessation and VEGF inhibitor therapy (eg, ranibizumab, bevacizumab).

References

- Anti-VEGF compounds in the treatment of neovascular age-related macular degeneration

This patient likely has **age-related macular degeneration (AMD)**, the leading cause of blindness in industrialized countries. AMD occurs in

Exhibit Display

AMD, Calcified Drusen (#1) AMD, Exudative

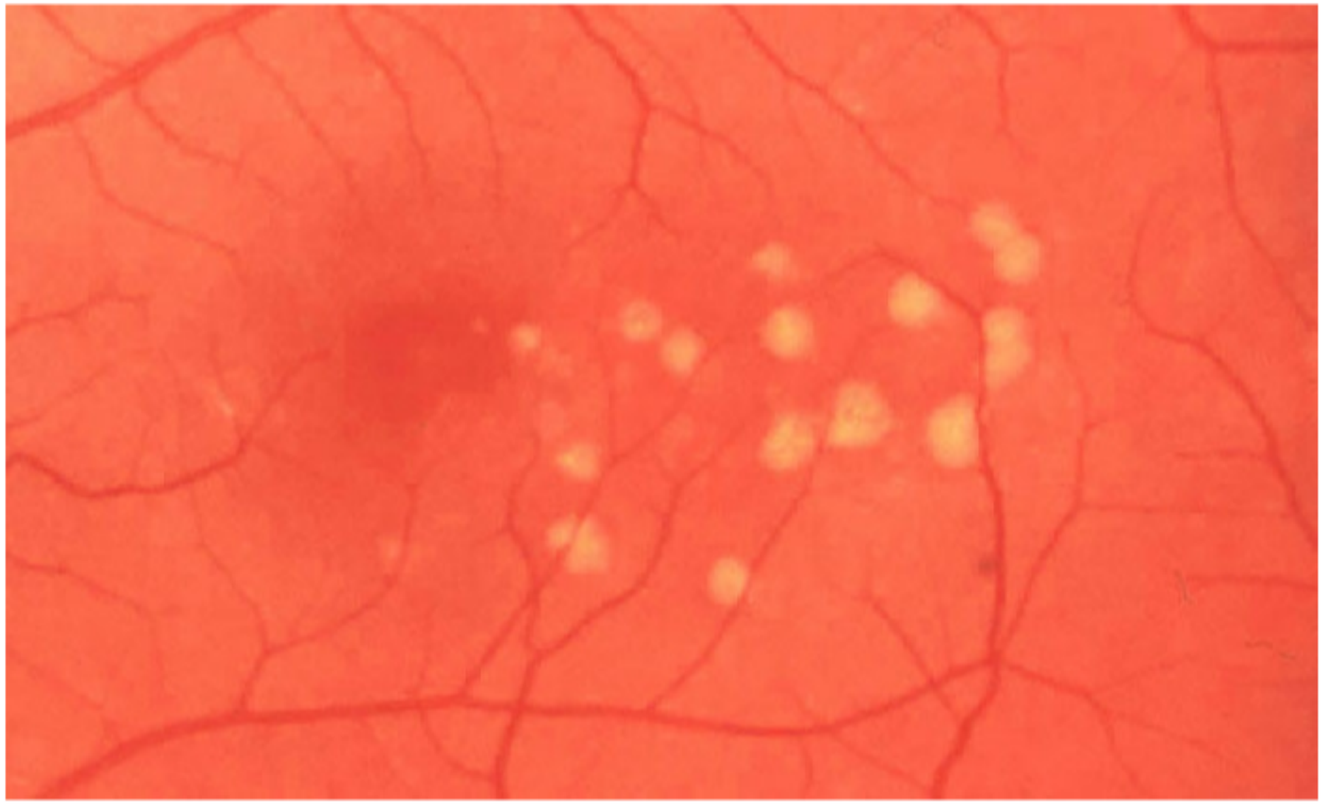

Zoom In Zoom Out Reset Add To New Card | Existing Card

- Anti-VEGF compounds in the treatment of neovascular age-related macular degeneration

This patient likely has **age-related macular degeneration (AMD)**, the leading cause of blindness in industrialized countries. AMD occurs in

Exhibit Display

AMD, Calcified Drusen (#1) AMD, Exudative

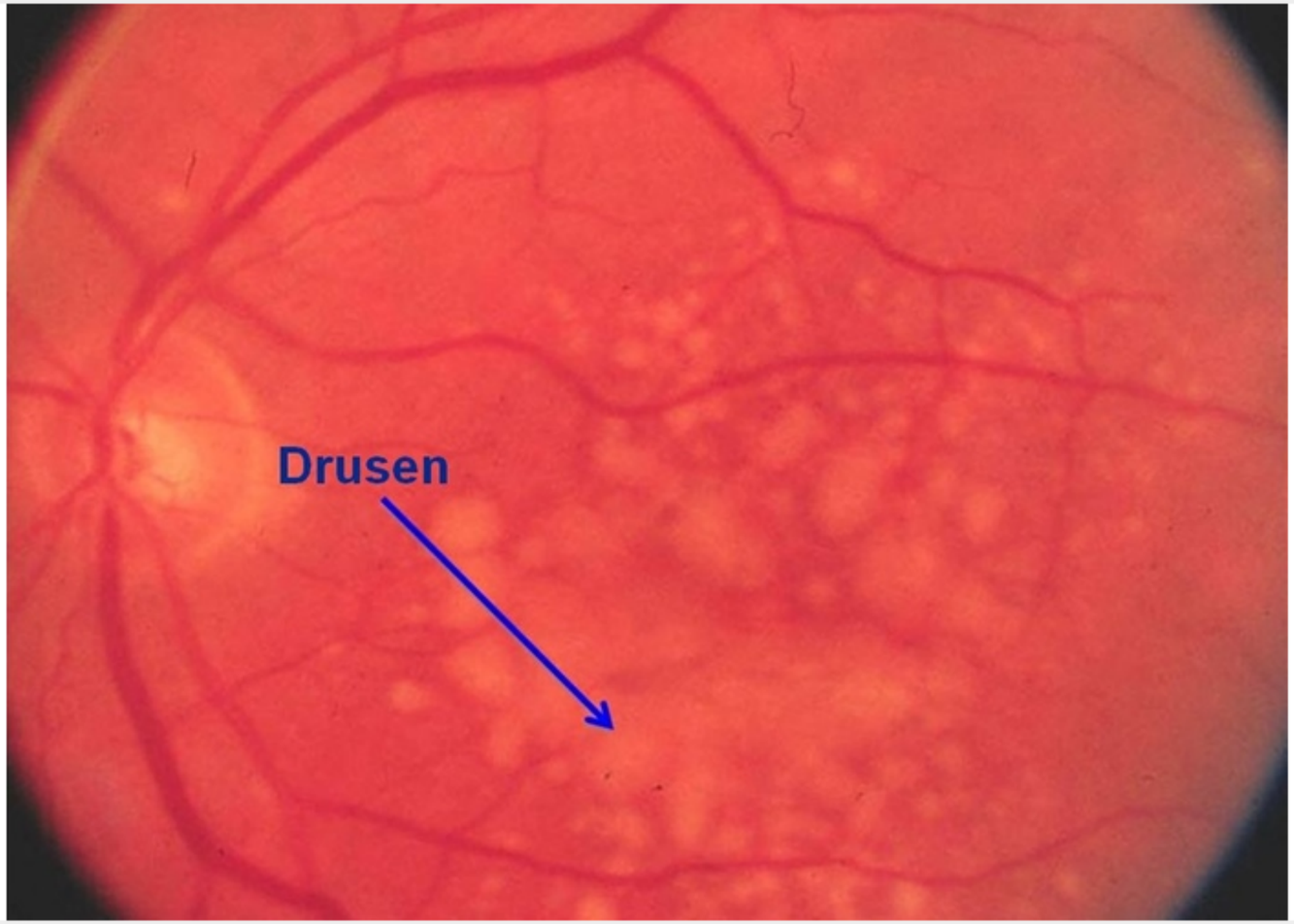

Zoom In Zoom Out Reset Add To New Card | Existing Card

- Anti-VEGF compounds in the treatment of neovascular age-related macular degeneration

This patient likely has **age-related macular degeneration (AMD)**, the leading cause of blindness in industrialized countries. AMD occurs in

Exhibit Display

Zoom In | Zoom Out | Reset | Add To New Card | Existing Card

- Anti-VEGF compounds in the treatment of neovascular age-related macular degeneration